# Cytoponction pancréatique pour suspicion d'adénocarcinome canalaire : diagnostics différentiels et pièges

## Carrefour Pathologie 2021

*Benoît Terris*

*Service de Pathologie, Hôpital Cochin*

MÉDECINE PARIS CENTRE
Santé
Université de Paris

# Adénocarcinome pancréatique: Incidence

- Tumeurs solides du pancréas:
  - Adénocarcinome canalaire
- Tumeur rare mais incidence en augmentation :
  - 6 000 nouveaux cas/an en 2006
  - 12 000 en 2012
  - 14 000 aujourd'hui
- Troisième cause de mortalité par cancer (5800 décès en 2018) :
  - pourrait se hisser à la deuxième place d'ici à 2030-2040 devant le cancer du poumon et le cancer colorectal.
- Echoendosopie :
  - Examen permet d'évaluer l'extension loco-régionale et d'apporter une preuve histologique

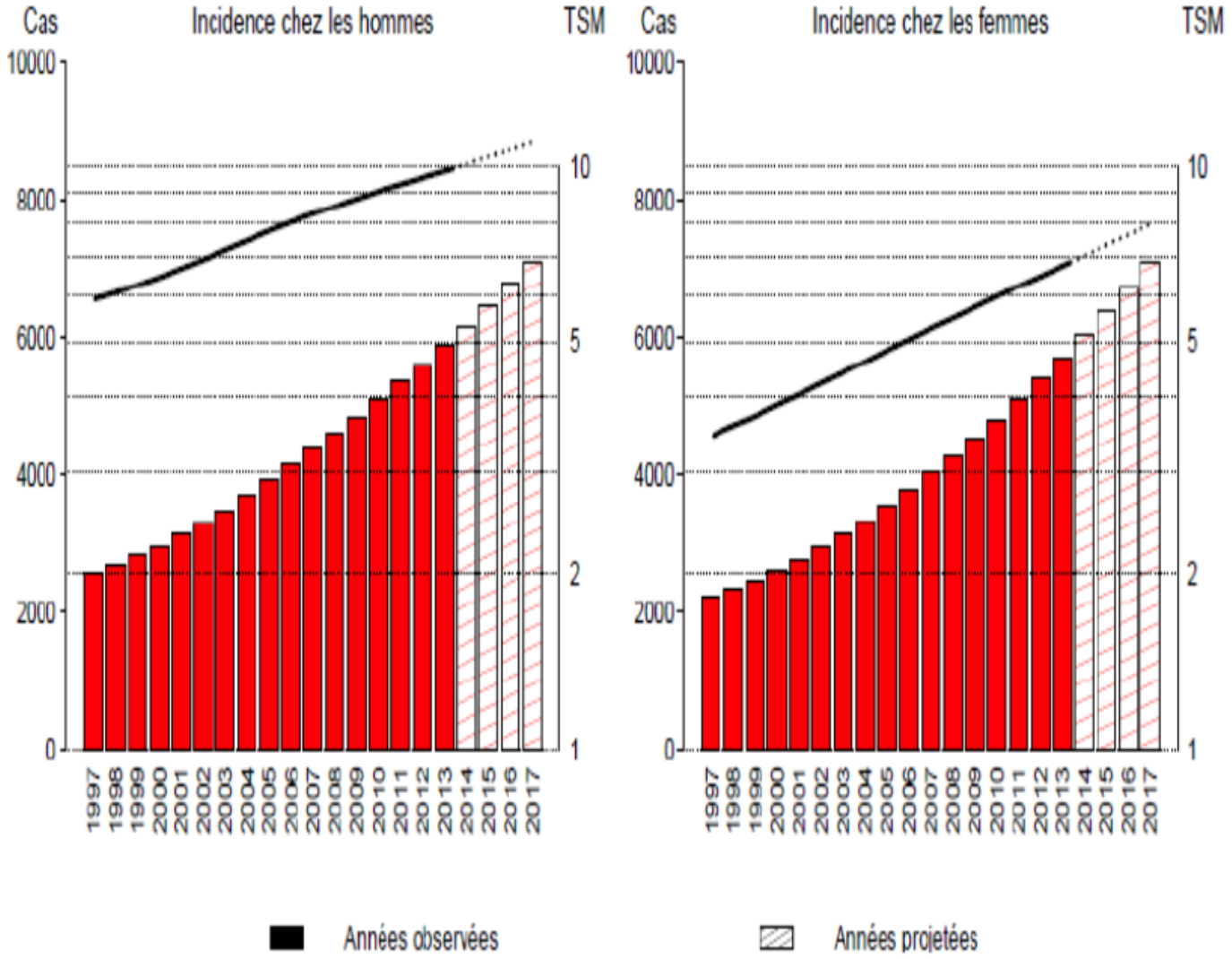

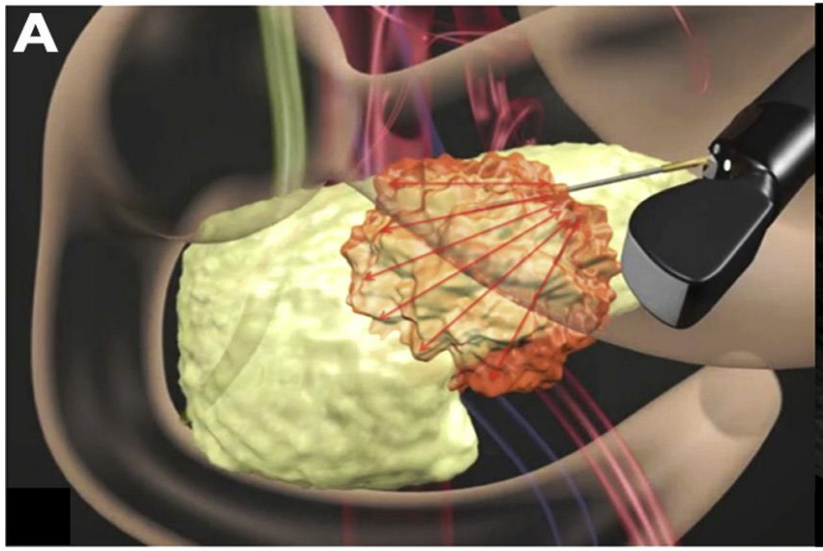
A

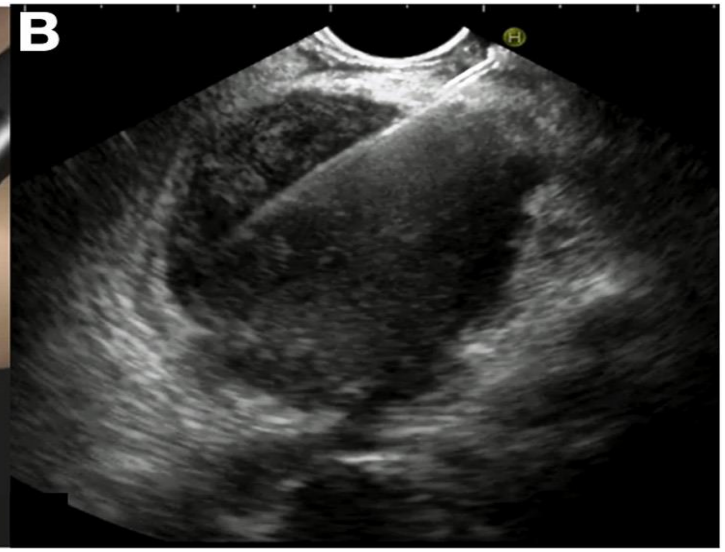
B

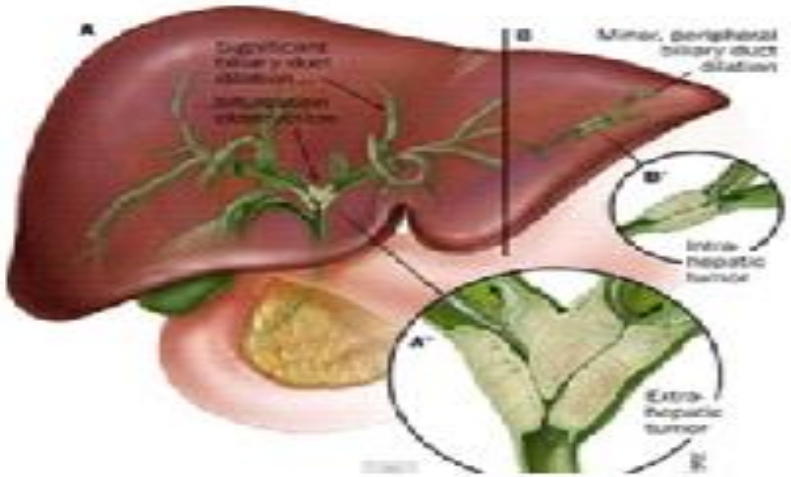
A
B
Minor, peripheral biliary duct dilation
Intra-hepatic tumour
Extra-hepatic tumour

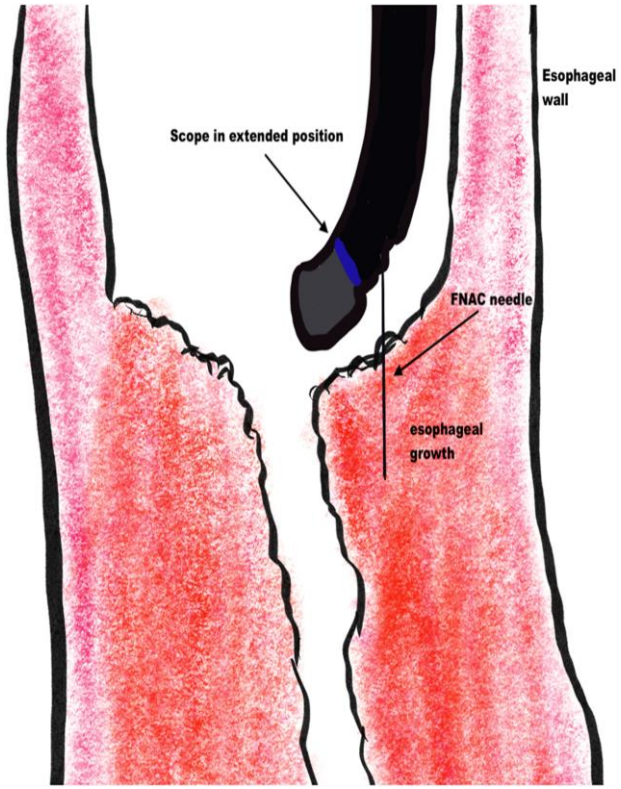
Esophageal wall
Scope in extended position
FNAC needle
esophageal growth

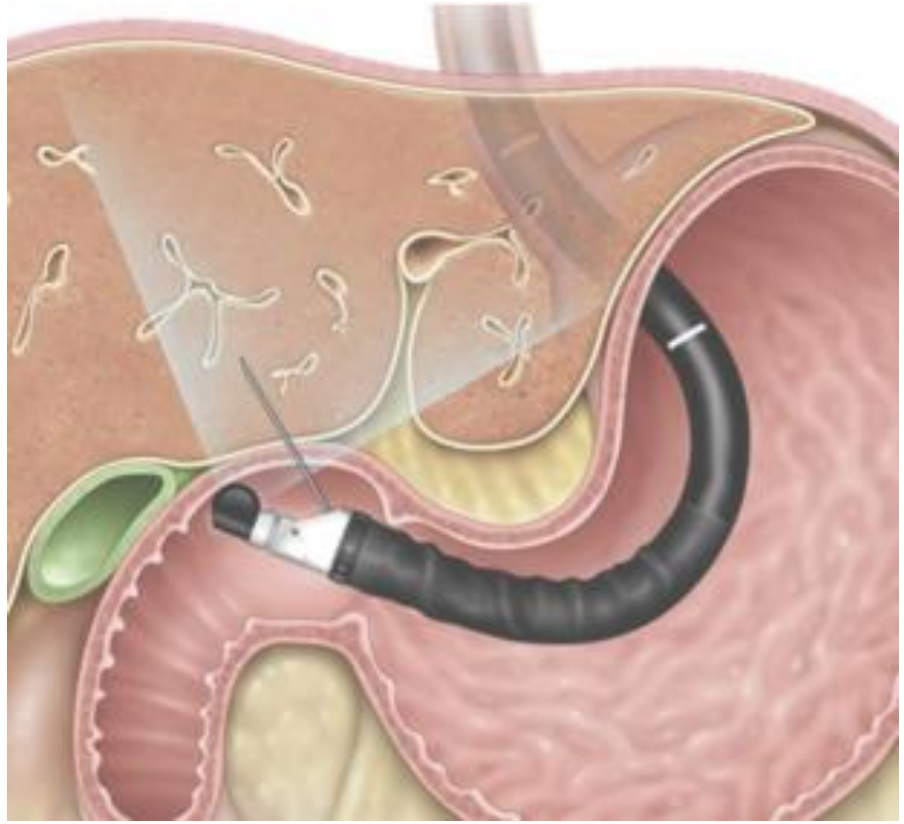

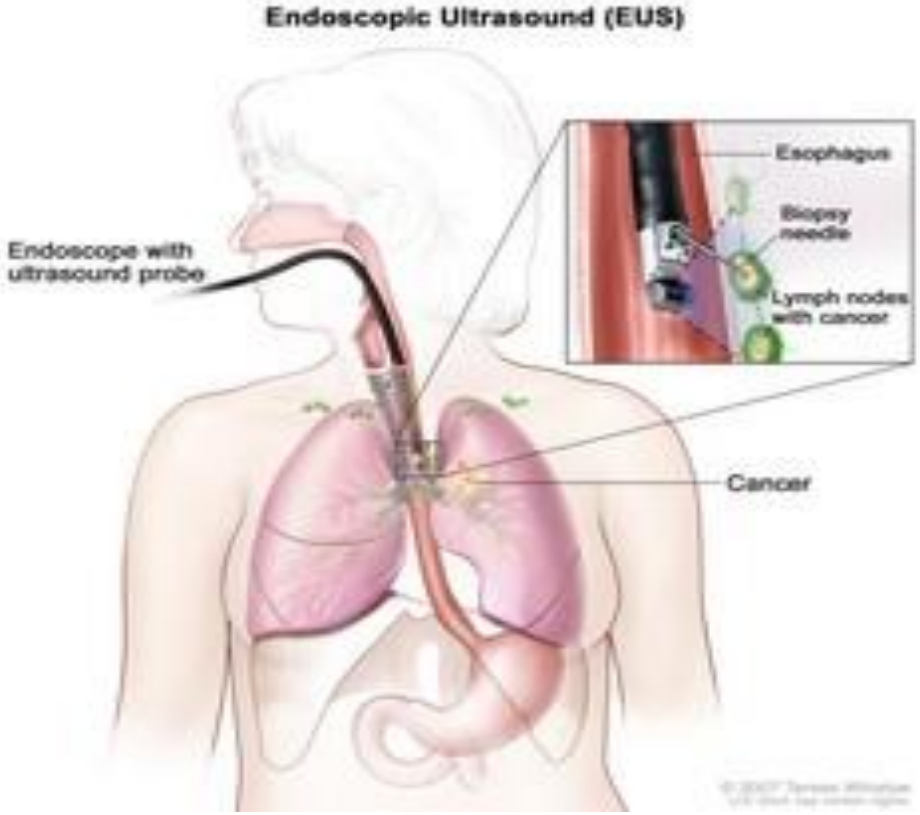
Endoscopic Ultrasound (EUS)
Endoscope with ultrasound probe
Esophagus
Biopsy needle
Lymph nodes with cancer
Cancer

# Peut-on opérer une lésion bilio-pancréatique sans preuve anatomopathologique ?

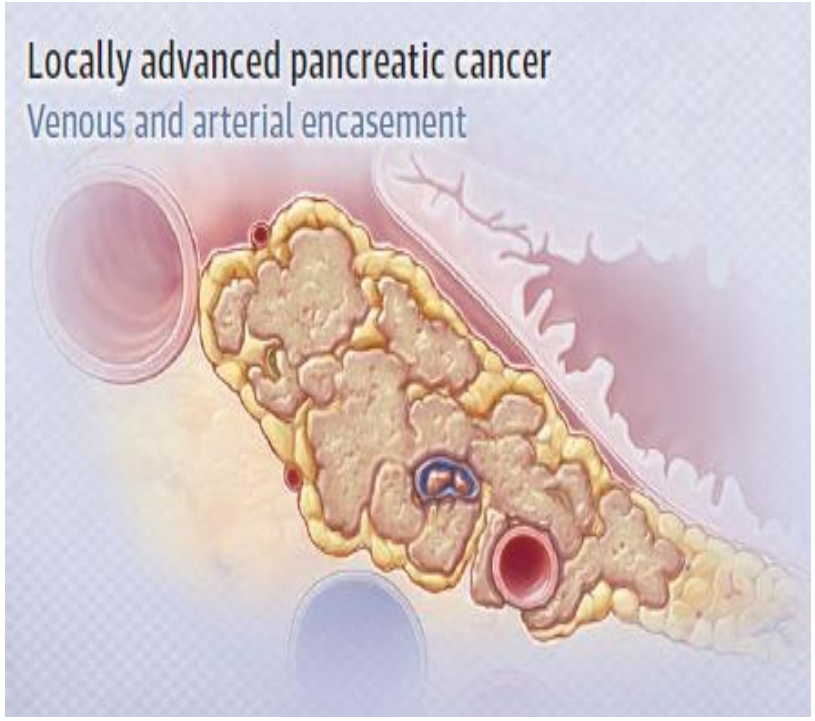


**Thésaurus National de Cancérologie Digestive©**

24/01/2021

- **Elle est indiquée dans trois situations** :
  - (i) doute diagnostique avec une lésion bénigne ;
  - (ii) tumeur non résécable mais sans métastase facilement accessible par voie transpariétale, pour avoir une preuve histologique avant de débuter le traitement médical ;
  - (iii) tumeur potentiellement résécable si un traitement néoadjuvant est envisagé.

- Il est important de rappeler que la preuve cyto/histologique de malignité n'est **pas systématique ni nécessaire avant la résection chirurgicale** pour une maladie résécable d'emblée, et qu'une biopsie non informative ne doit pas retarder la résection chirurgicale en cas de forte suspicion clinique de cancer pancréatique.

- **A contrario une ponction sous EE et des biopsies d'ampoule seront conseillées** pour éliminer une pancréatite auto-immune de type 1 en cas de tumeur de la tête du pancréas chez un patient à risque chirurgical élevé (cf. ci-dessous) ou quand la tumeur présente certaines caractéristiques (absence de dilatation du canal de Wirsung en amont de la masse, aspect de cholangite associé). Une aiguille à biopsie de 20G ou 22G sera alors privilégiée.

# Dg différentiel clinique des ADK du pancréas

## Suspicion de malignité pancréatique

**AEG**

**Ictère**

**Masse**

**Dilatation VBP ± canal de Wirsung**

| Unexpected benign | $n = 86$ |
|---|---|
| Chronic fibrosing pancreatitis | 52 (60 %) |
| Chronic fibrosing cholangitis | 17 (20 %) |
| Autoimmune pancreatitis | 9 (11 %) |
| Serous cystadenoma | 2 (2 %) |
| No abnormalities | 2 (2 %) |
| Other[a] | 4 (5 %) |

| Mass[a] | PD and/or CBD dilatation[b] | PA confirmed diagnosis | | |
|---|---|---|---|---|
| | | Benign $n = 86$ | Malignant[c] $n = 1,222$ | Total $n = 1,308$ |
| No | No | 10 (34 %) | 19 (66 %) | 29 (100 %) |
| | Yes | 39 (10 %) | 360 (90 %) | 399 (100 %) |
| Yes | No | 10 (18 %) | 47 (82 %) | 57 (100 %) |
| | Yes | 27 (3 %) | 796 (97 %) | 823 (100 %) |

## Fréquence des pathologies bénignes sur pancréatectomie

Sur 344 pancréatectomies = 7% pathologies bénignes

Gerritsen, 2014

# Dg différentiel clinique des ADK du pancréas

## T SOLIDE PANCRÉAS <15MM (N=394)

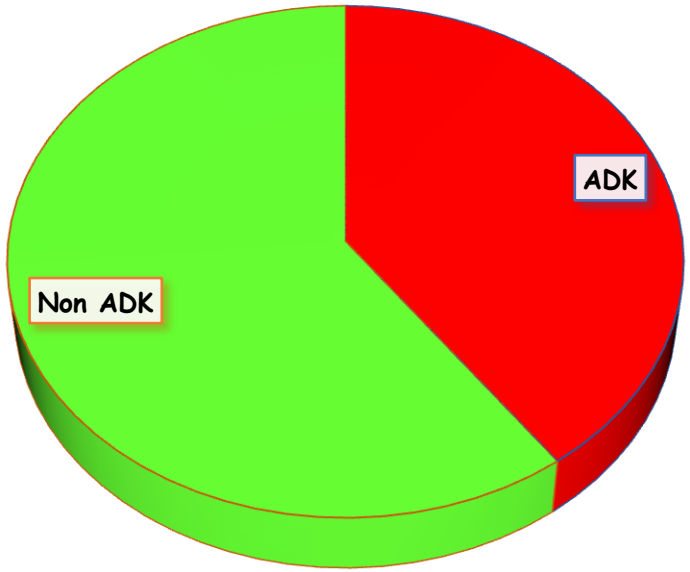


## 156 TNE, 26 métastases, 64 autres

| | No | Age [years] | Benign | Malignant | Surgery |
|---|---|---|---|---|---|
| All | 64 | 53±15 [18 - 84] | | | |
| Focal pancreatitis | 25 | 54±16 [20 - 84] | 25 | 0 | 9 |
| SMCA | 15 | 56±12 [38 - 74] | 15 | 0 | 1 |
| IPMN mucin filled | 8 | 62±10 [47 - 77] | 6 | 2 | 5 |
| SPT | 5 | 37±13 [18 - 50] | 4 | 1 | 5 |
| Intrapancreatic accessory spleen | 4 | 44±21 [29 - 75] | 4 | 0 | 2 |
| Lipoma | 2 | 65 [53 - 77] | 2 | 0 | 0 |
| Hamartoma | 2 | 59 [55 - 63] | 2 | 0 | 0 |
| NHL | 2 | 41 [36 - 45] | 0 | 2 | 0 |
| Necrosis | 1 | 35 | 1 | 0 | 0 |

MANUSCRIT

*Dietrich, 2016*

# Ponction sous échoendoscopie (PEE)
## *Diagnostic*

- **Facteurs déterminants du résultat**
  - **Expérience échoendoscopiste**
    - **Identification et localisation de la lésion**
    - **Ciblage adéquat**
  - **Expérience pathologiste**
    - **Traitement approprié du prélèvement**
    - **Interprétation adéquate**

Table 1. Sensitivity and diagnostic accuracy in six groups of 50 procedures consecutively carried out during the study period.

| Number of cases | Sensitivity (95% CI) | Accuracy (95% CI) |
|---|---|---|
| 1–50 | 52.3 (37.5–67.0) | 58.0 (44.3–71.7) |
| 51–100 | 53.2 (38.9–67.5) | 56.0 (42.2–69.8) |
| 101–150 | 59.6 (45.5–73.6) | 62.0 (48.6–75.5) |
| 151–200 | 73.2 (59.6–86.7) | 78.0 (66.5–89.5) |
| 201–250 | 69.6 (56.3–82.9) | 71.4 (58.8–84.1) |
| >251 | 87.0 (78.1–96.0) | 87.5 (78.8–96.2) |

- **Moins de 5 passages biopsiques après 100 PEE**
- **Réduction des complications après 200 PEE**

*Del Vecchio Blanco, 2021*

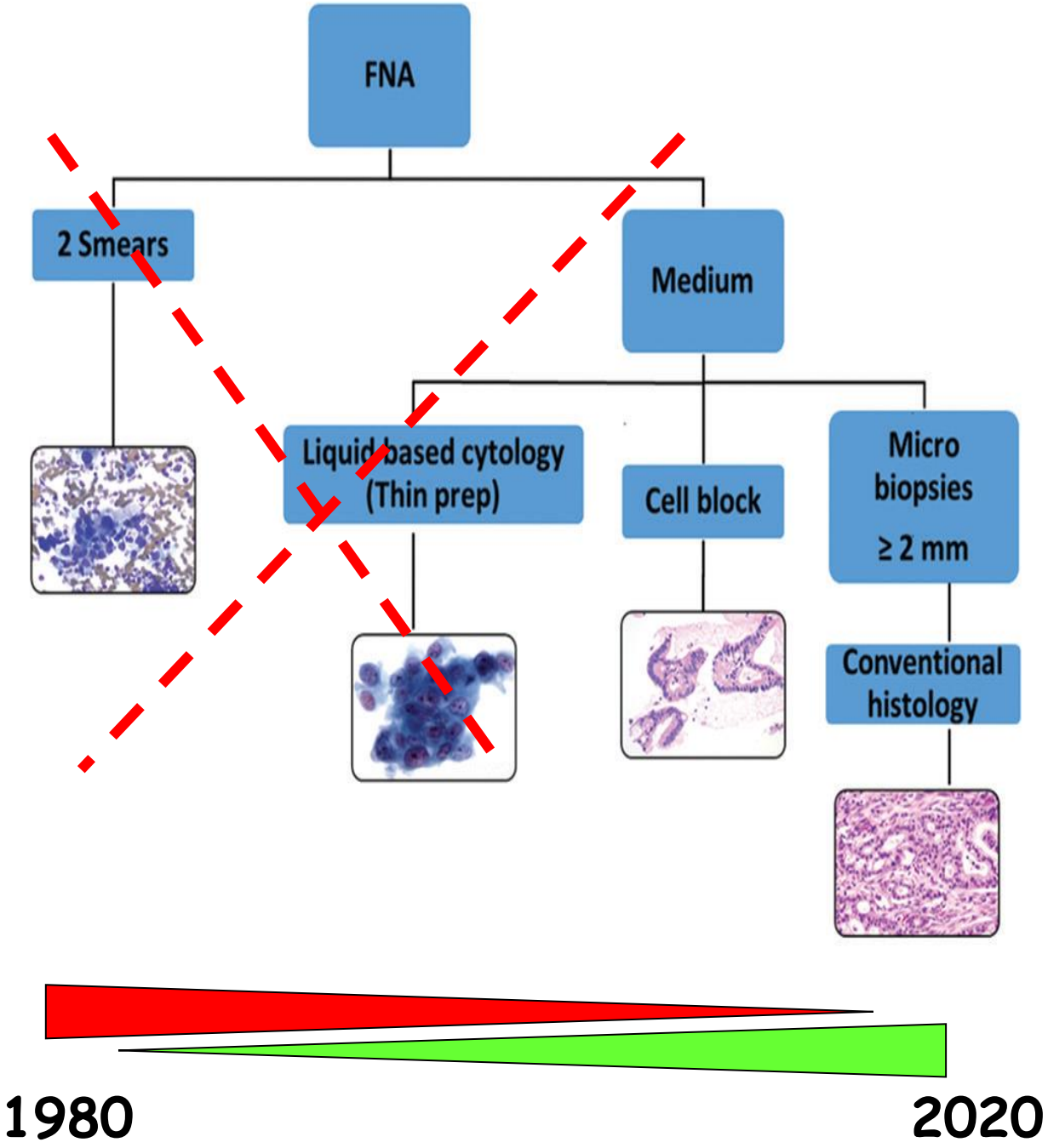


## Endoscopic ultrasound (EUS)-guided fine needle biopsy alone vs. EUS-guided fine needle aspiration with rapid onsite evaluation in pancreatic lesions: a multicenter randomized trial

**Conclusion** EUS-FNB alone is non-inferior to EUS-FNA + ROSE and is associated with fewer needle passes, shorter procedure time, and excellent histological yield at comparable cost.

## Endoscopic Ultrasound–guided Fine-needle Biopsy With or Without Rapid On-site Evaluation for Diagnosis of Solid Pancreatic Lesions: A Randomized Controlled Non-Inferiority Trial

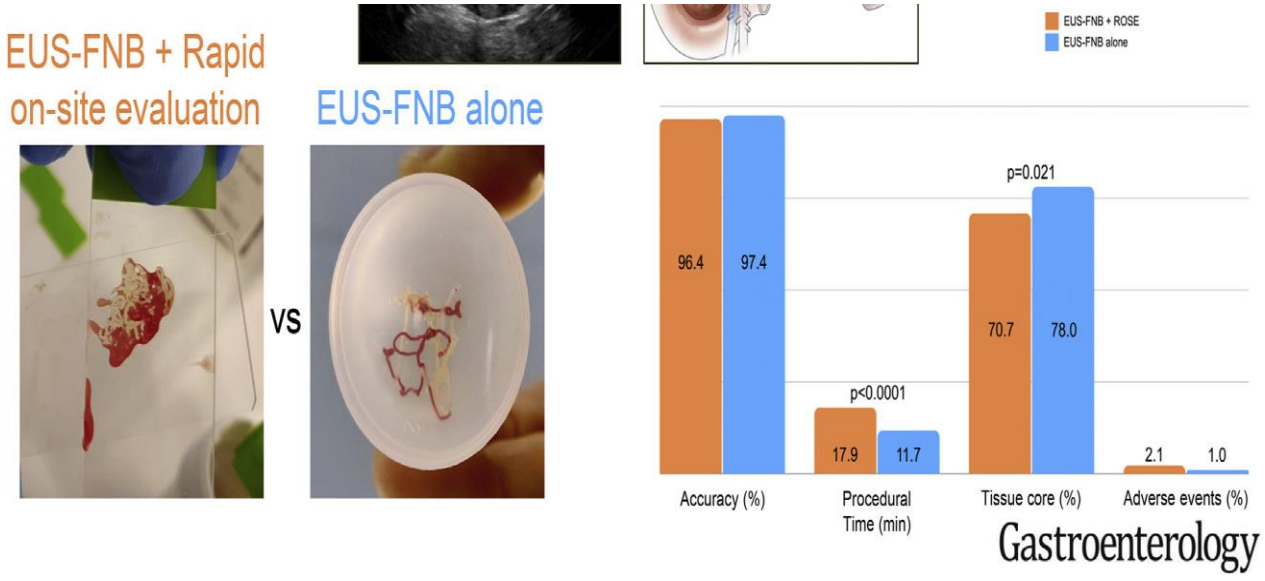


*Chen, 2021; Cruno, 2021*

# Fréquence des faux négatifs après PEE - FNB

## *Un évènement fréquent dans un centre expert ?*

PEE 1- (67 sur 2300) = 2,7% (Cochin : 2008-2018)

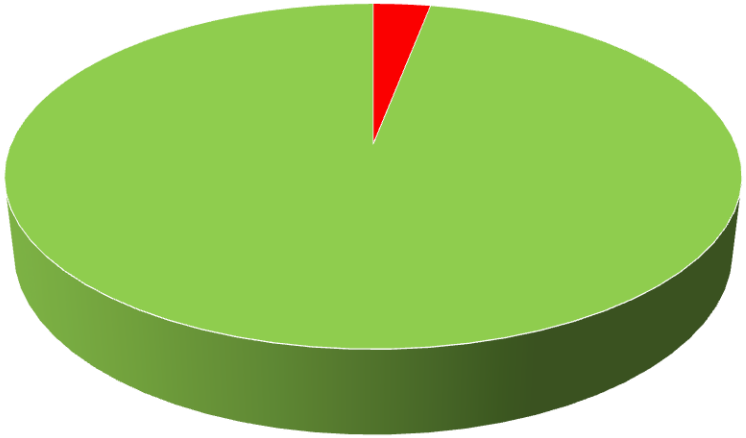


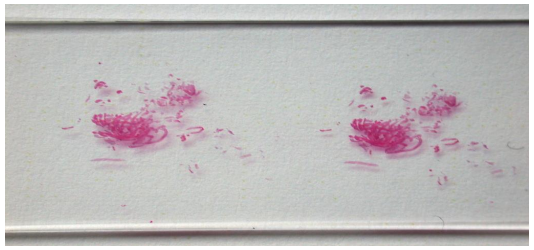

Niveaux



PEE 2- = 1,3%

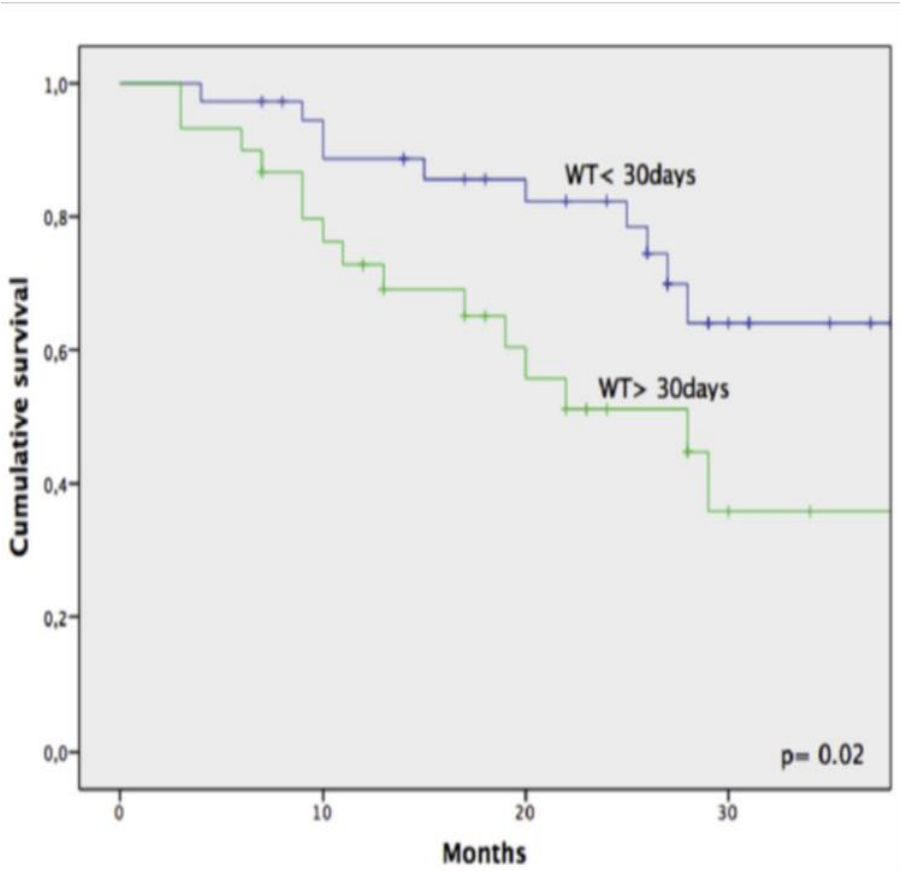


*Marchegiani, HPB, 2017*

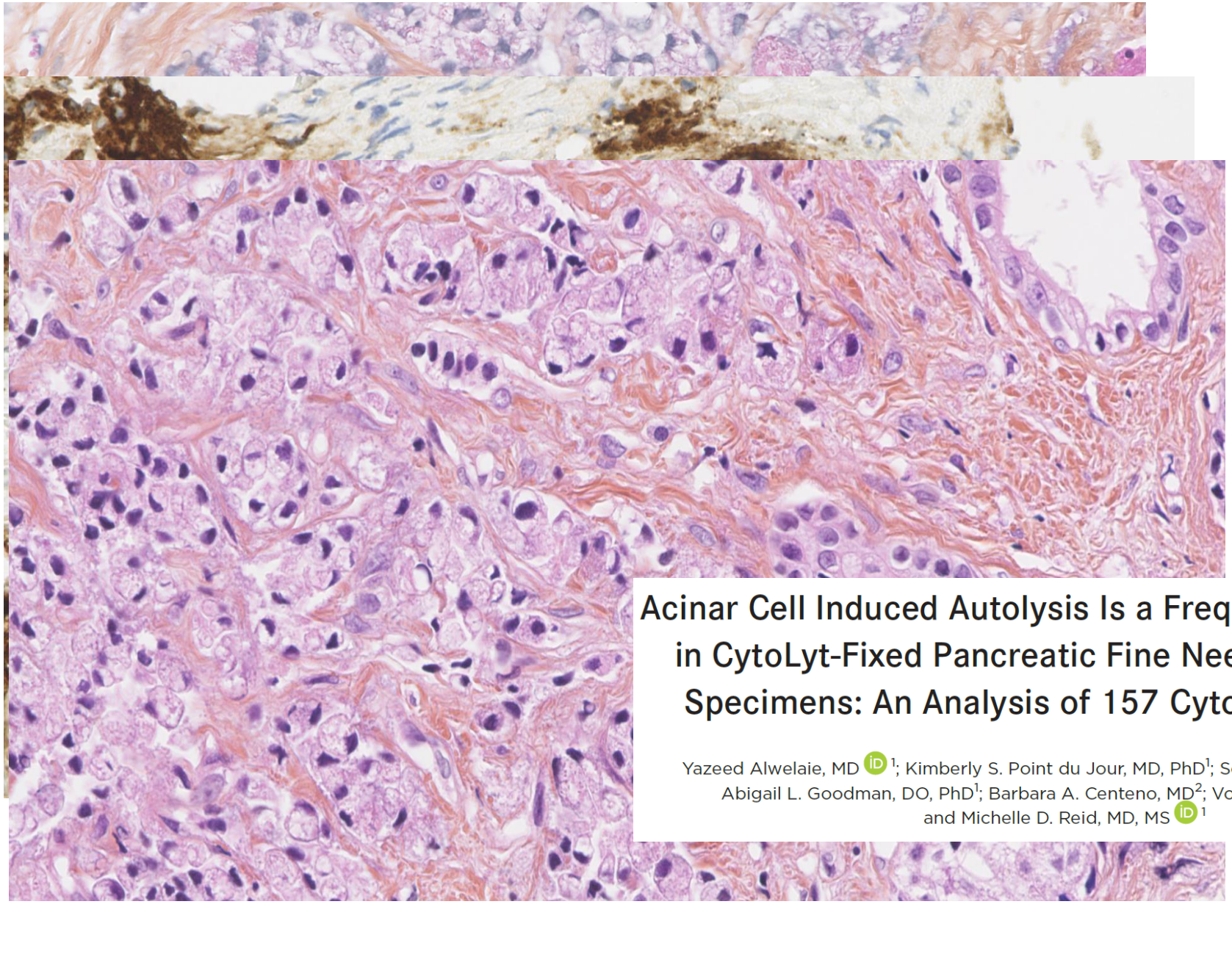

# Acinar Cell Induced Autolysis Is a Frequent Occurrence in CytoLyt-Fixed Pancreatic Fine Needle Aspiration Specimens: An Analysis of 157 Cytology Samples

Yazeed Alwelaie, MD [1]; Kimberly S. Point du Jour, MD, PhD[1]; Sonal Pandya, CT (ASCP)[1]; Abigail L. Goodman, DO, PhD[1]; Barbara A. Centeno, MD[2]; Volkan Adsay, MD [3]; and Michelle D. Reid, MD, MS [1]

# Démarche dg des T solides pancréatiques

**Tumeur solide**

**> 90%**

**Glandes tumorales +/- mucosécrétion +/- stroma abondant**

**Adénocarcinome canalaire**

**Densité cellulaire élevée avec peu ou pas de stroma**

**Différenciation tumorale prédominante**

**Acinaire**

**BCL10**

**Carcinome à cellules acinaires**

*pancréatoblastome*

**Neuro-endocrine**

**Chromogranine, synaptophysine, Ki67**

**Tumeur neuro-endocrine**

**Indéfinie**

**Beta-caténine**

**MUC6**

**Tumeur solide et pseudo-papillaire**

**Cystadénome séreux**

**Inhabituelle pour la localisation**

**Autres ac**

**Métastase**

# PEE – ADK canalaire conventionnel

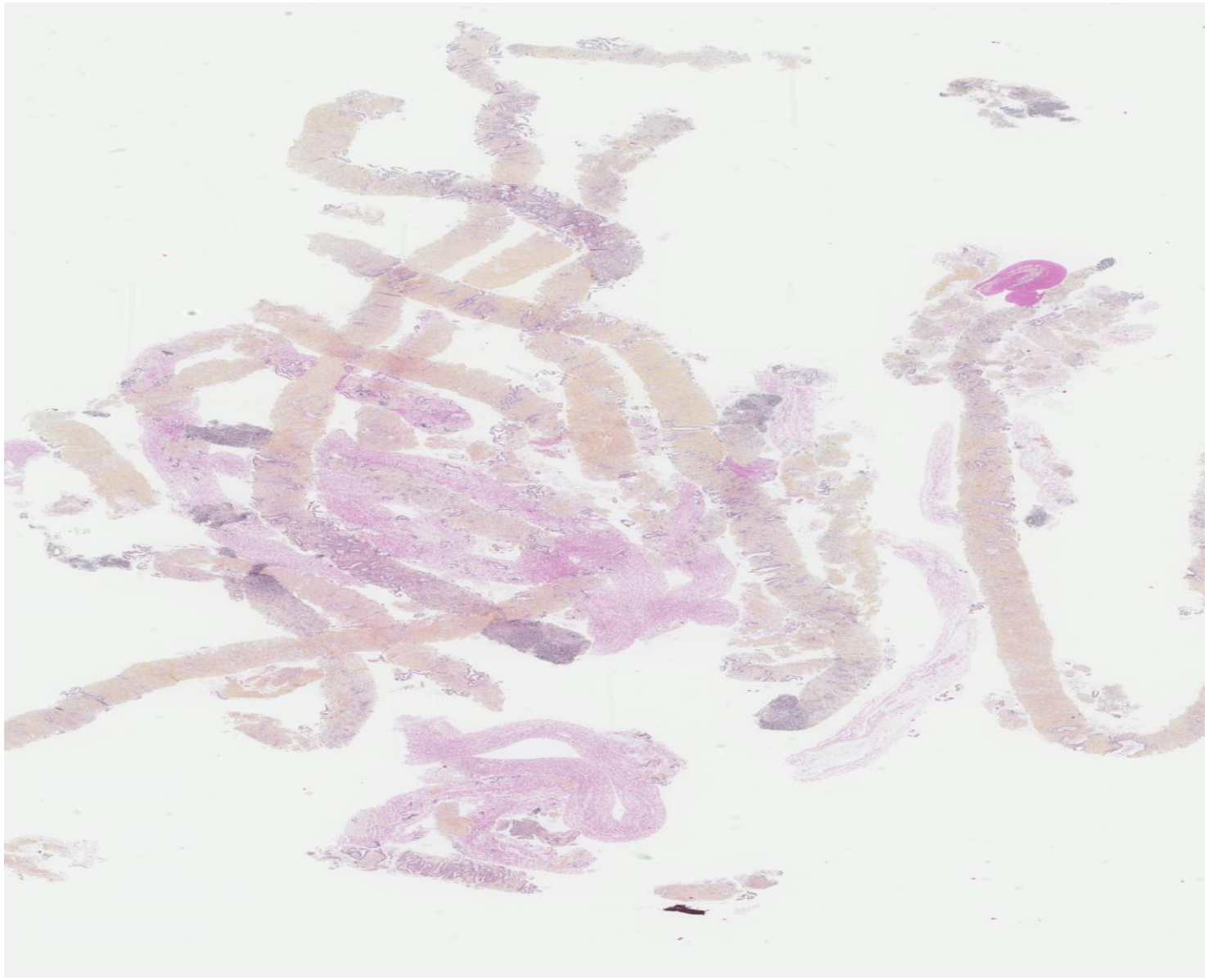

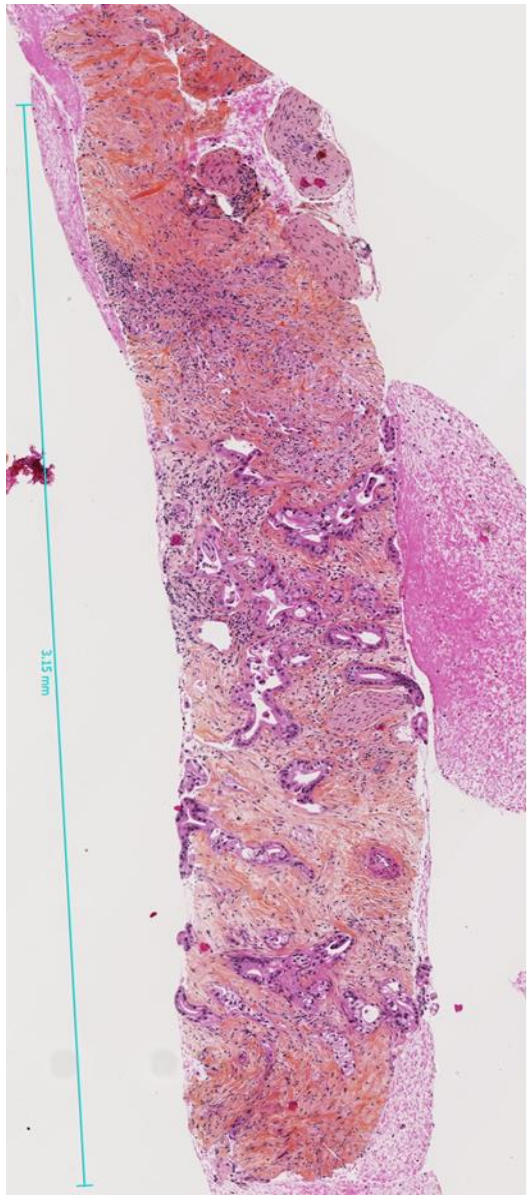


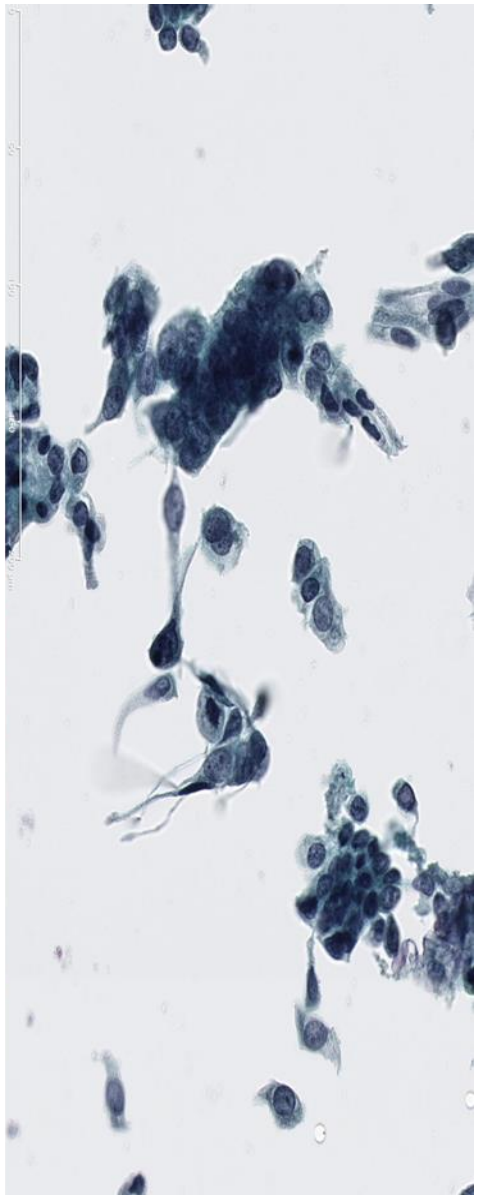

# PEE – ADK canalaire conventionnel

| *Markers* | *Pancreatic ductal adenocarcinoma* |
|---|---|
| CK7 | 45/46 ((98%) |
| CK17 | 38/46 (83%) |
| CK20 | 21/46 (46%) |
| CDX-2 | 10/46 (22%) |
| MUC1 | 77/81 (95%) |
| MUC2 | 2/81 (2%) |
| MUC5AC | 75/81 (93%) |

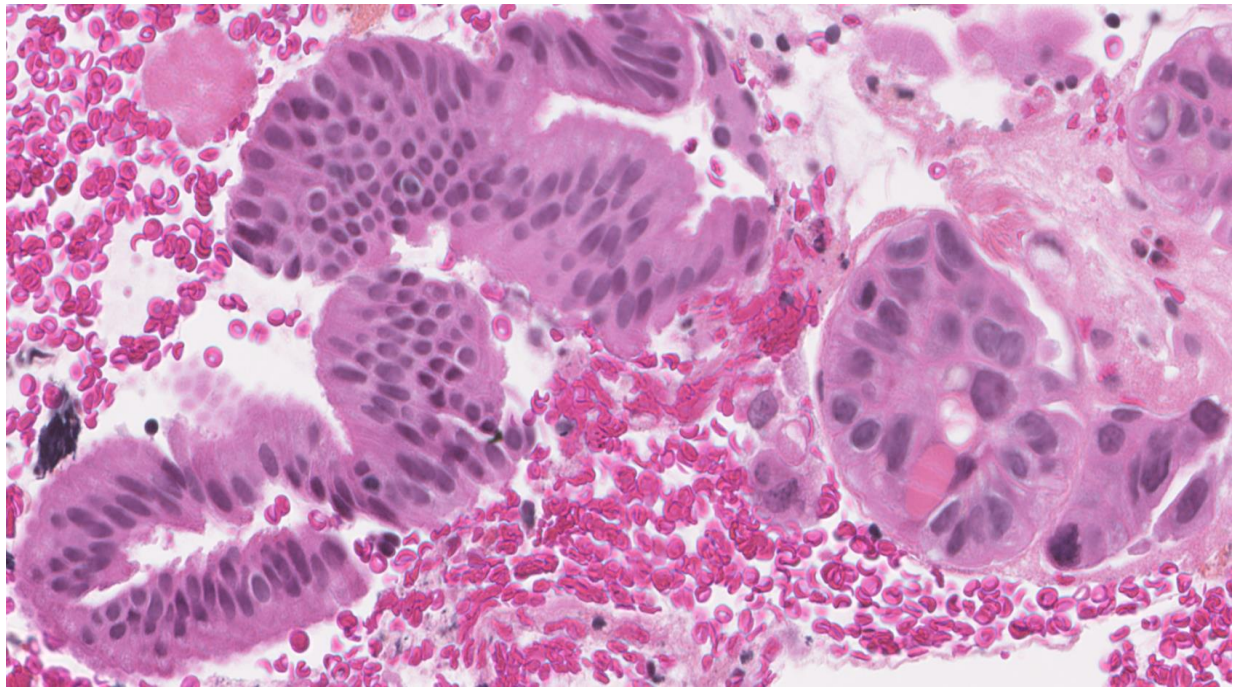

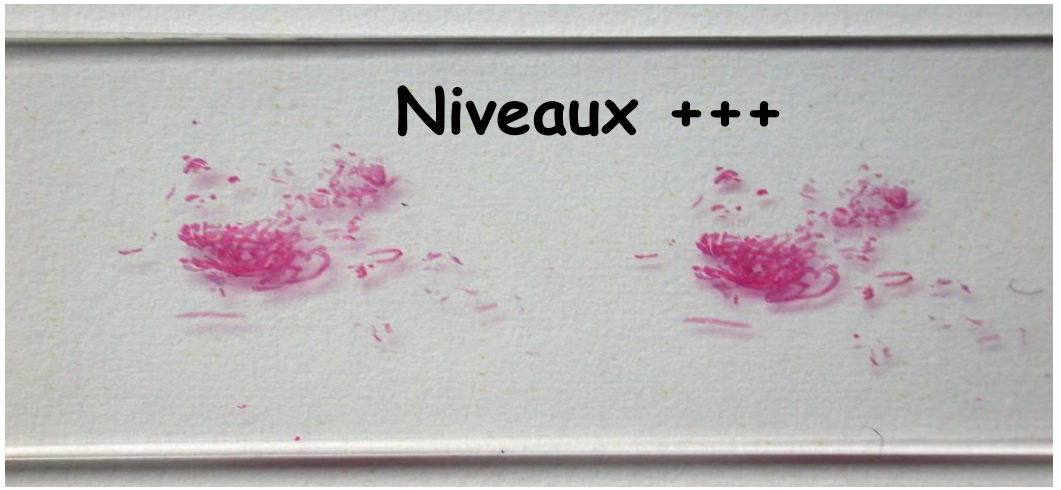

# PEE – ADK canalaire conventionnel

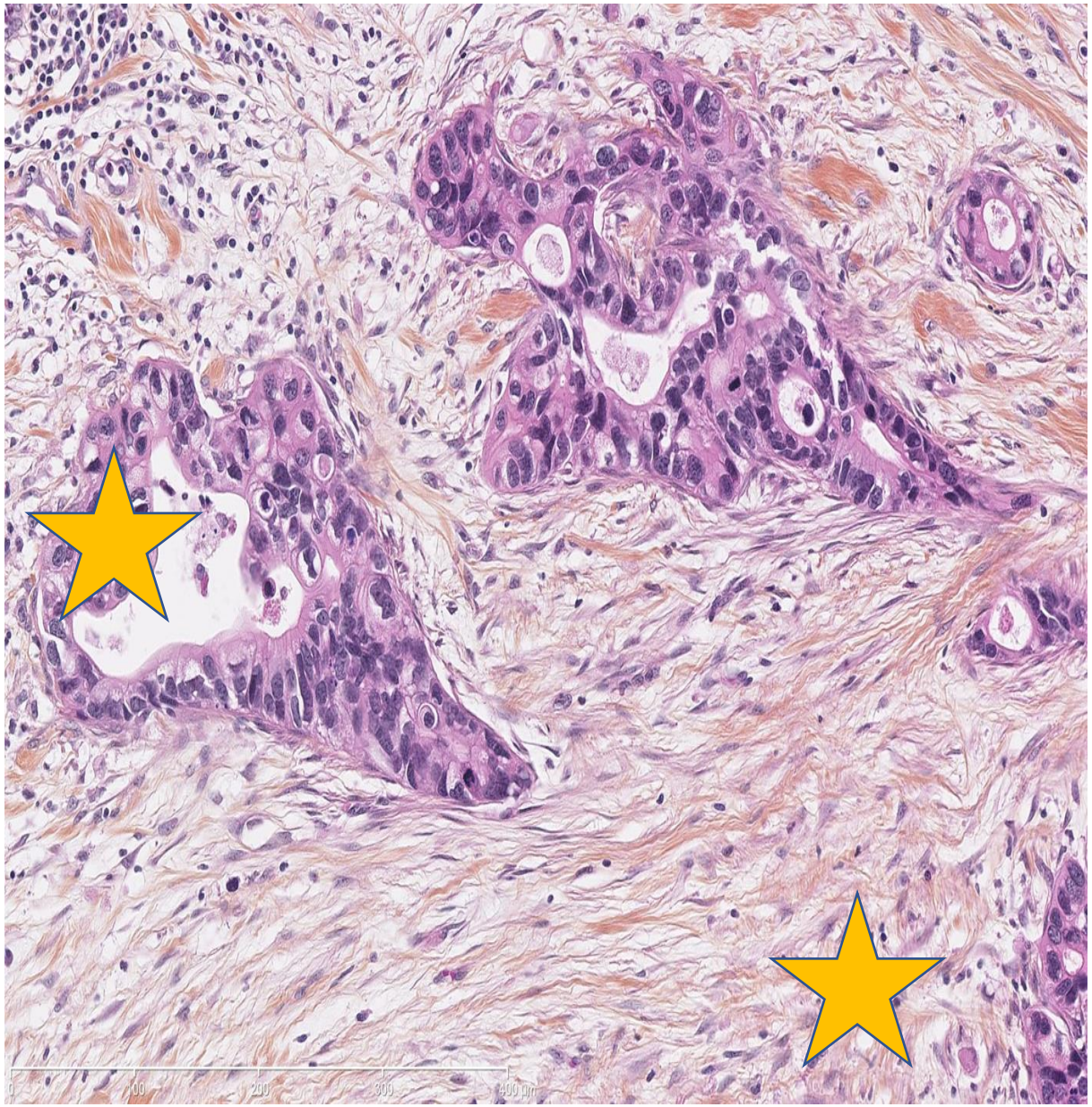

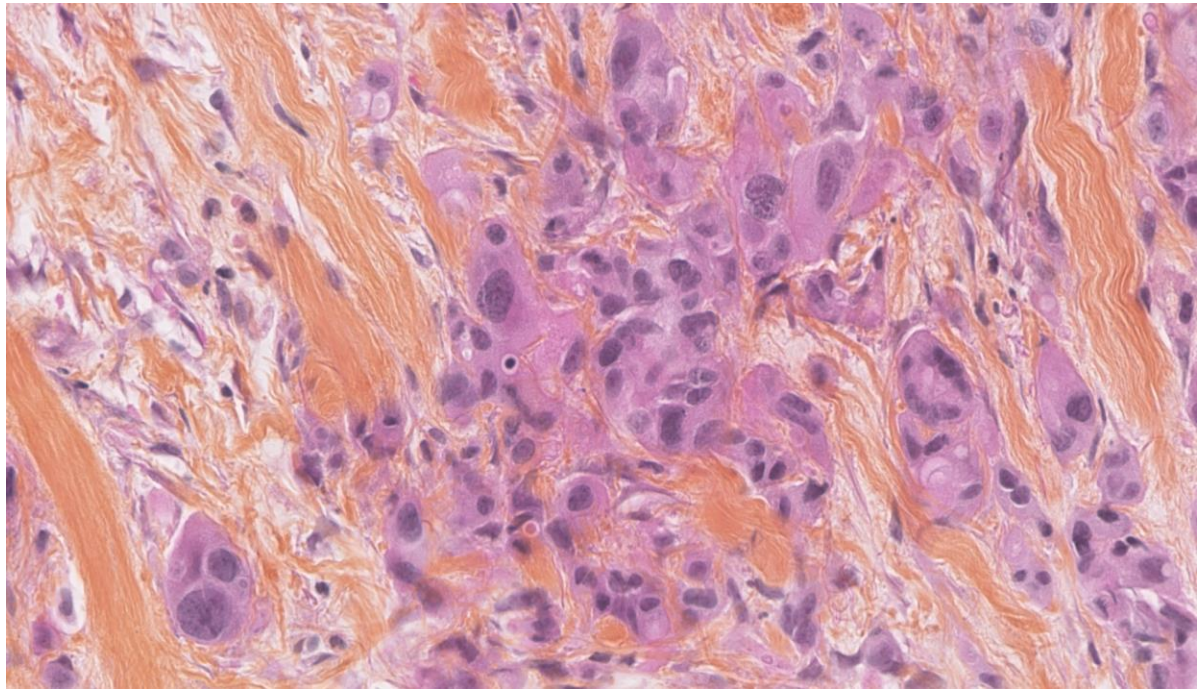

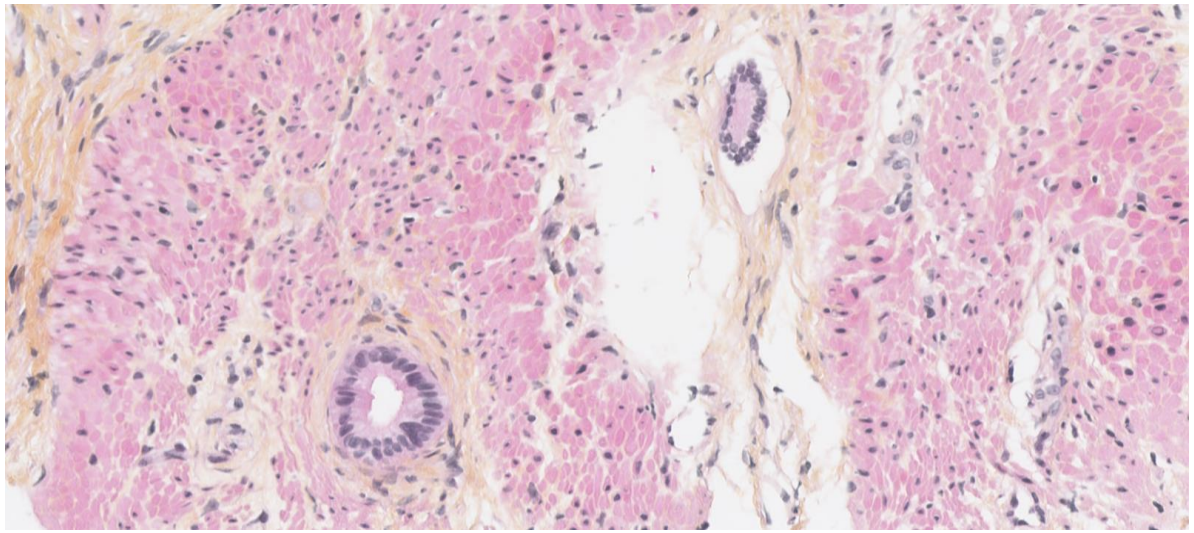

# PEE – ADK canalaire conventionnel

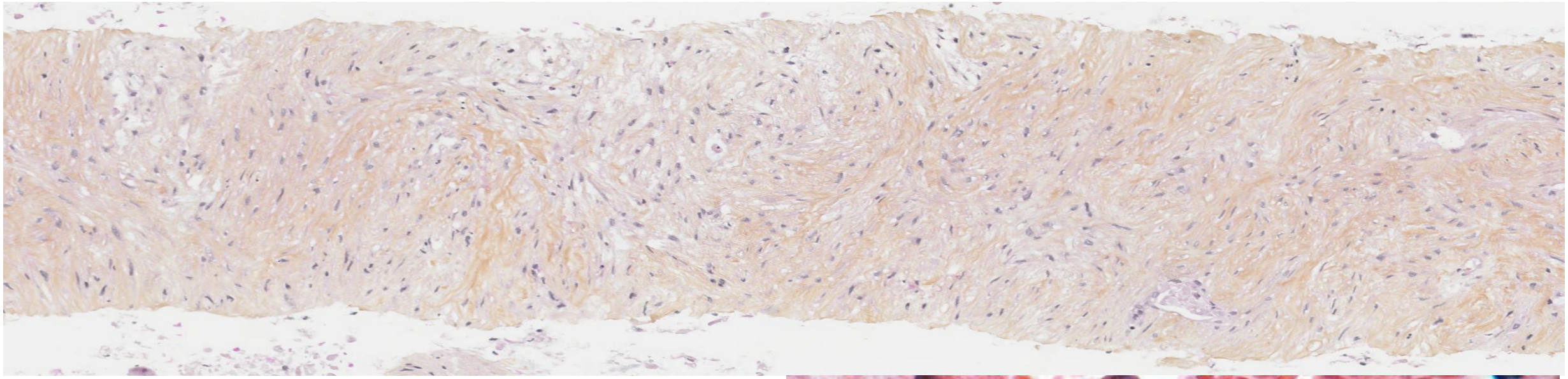

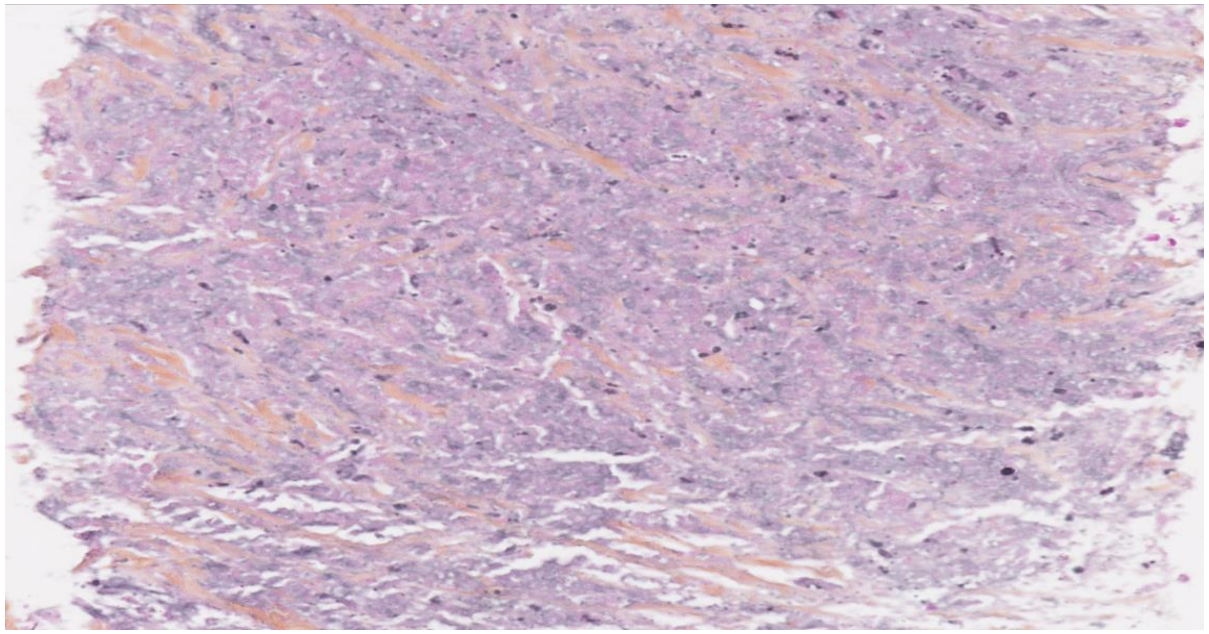

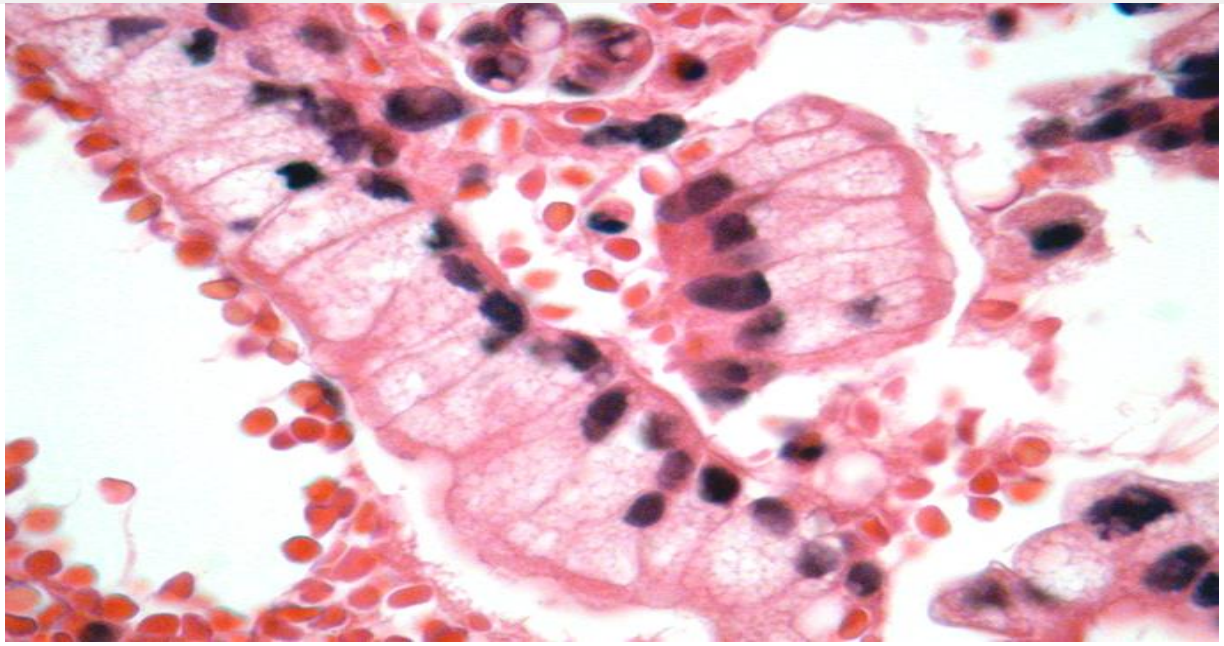

# PEE – variants d'ADK canalaire

| Variants d'ADK canalaire | |
|---|---|
| **Meilleur pronostic** | **Mauvais pronostic** |
| Mucineux (GNAS) | Adénosquameux |
| Ind ostéoclast. | Indifférencié |
| Médullaire (MSI) | Micropapillaire |
| | Hépatoïde |
| | ADK cellules indépendantes |

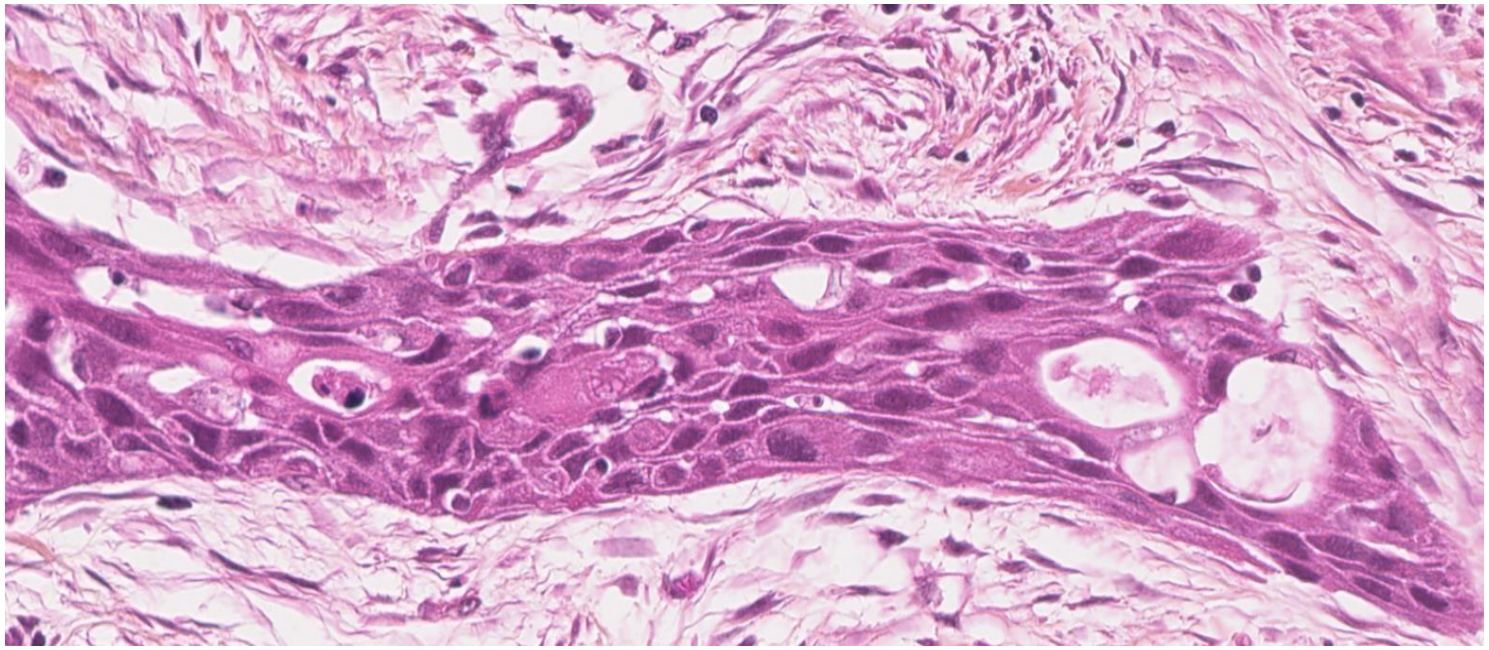

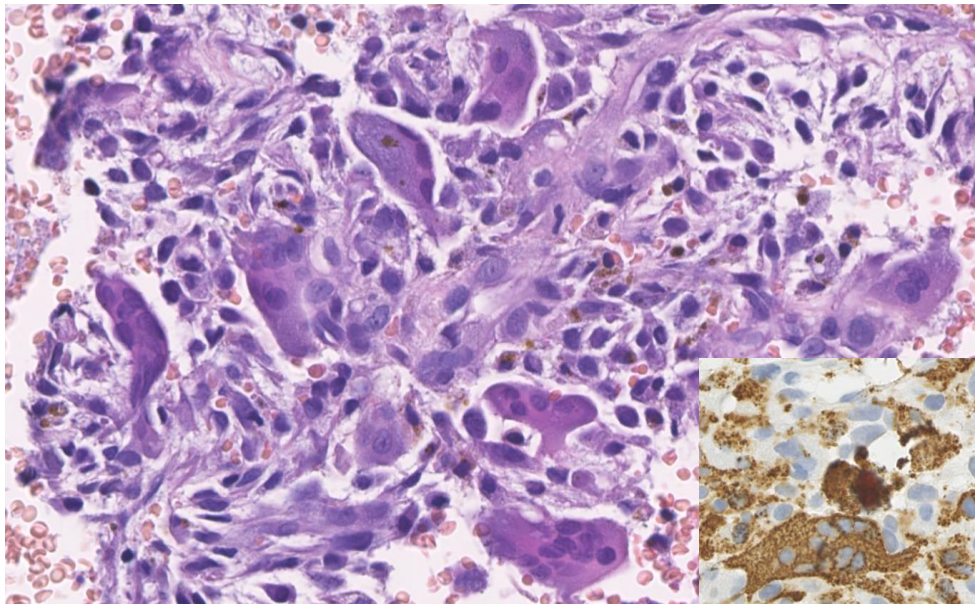

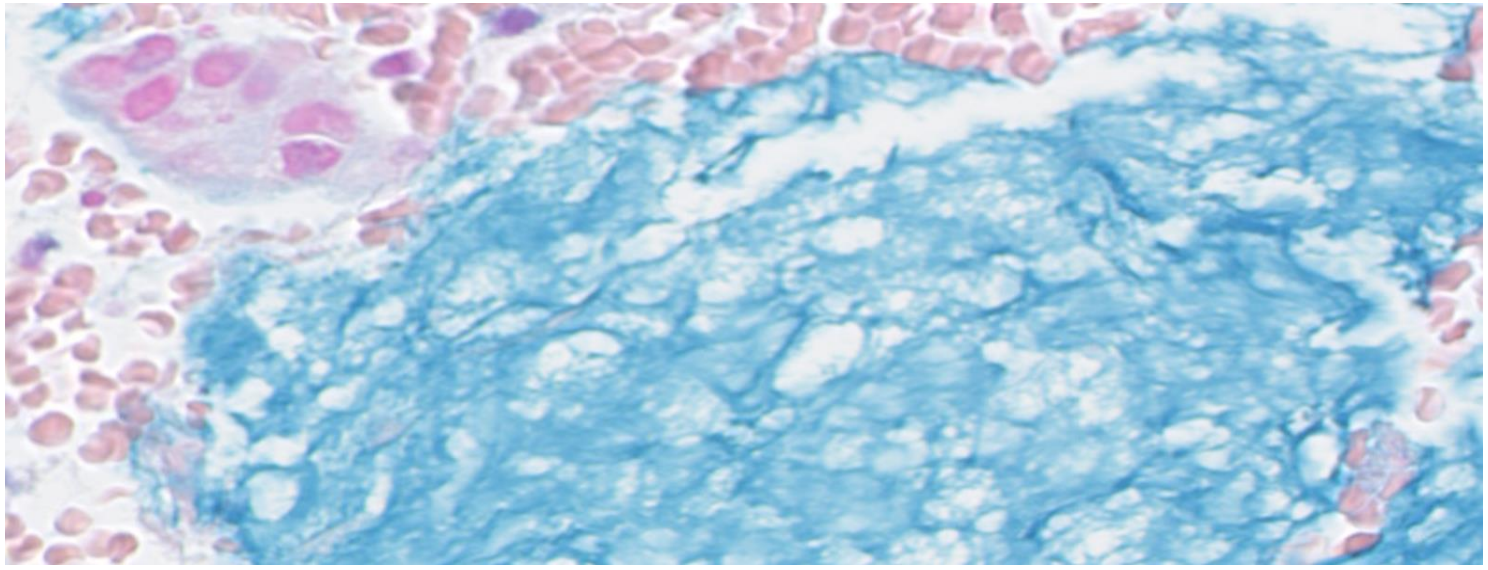

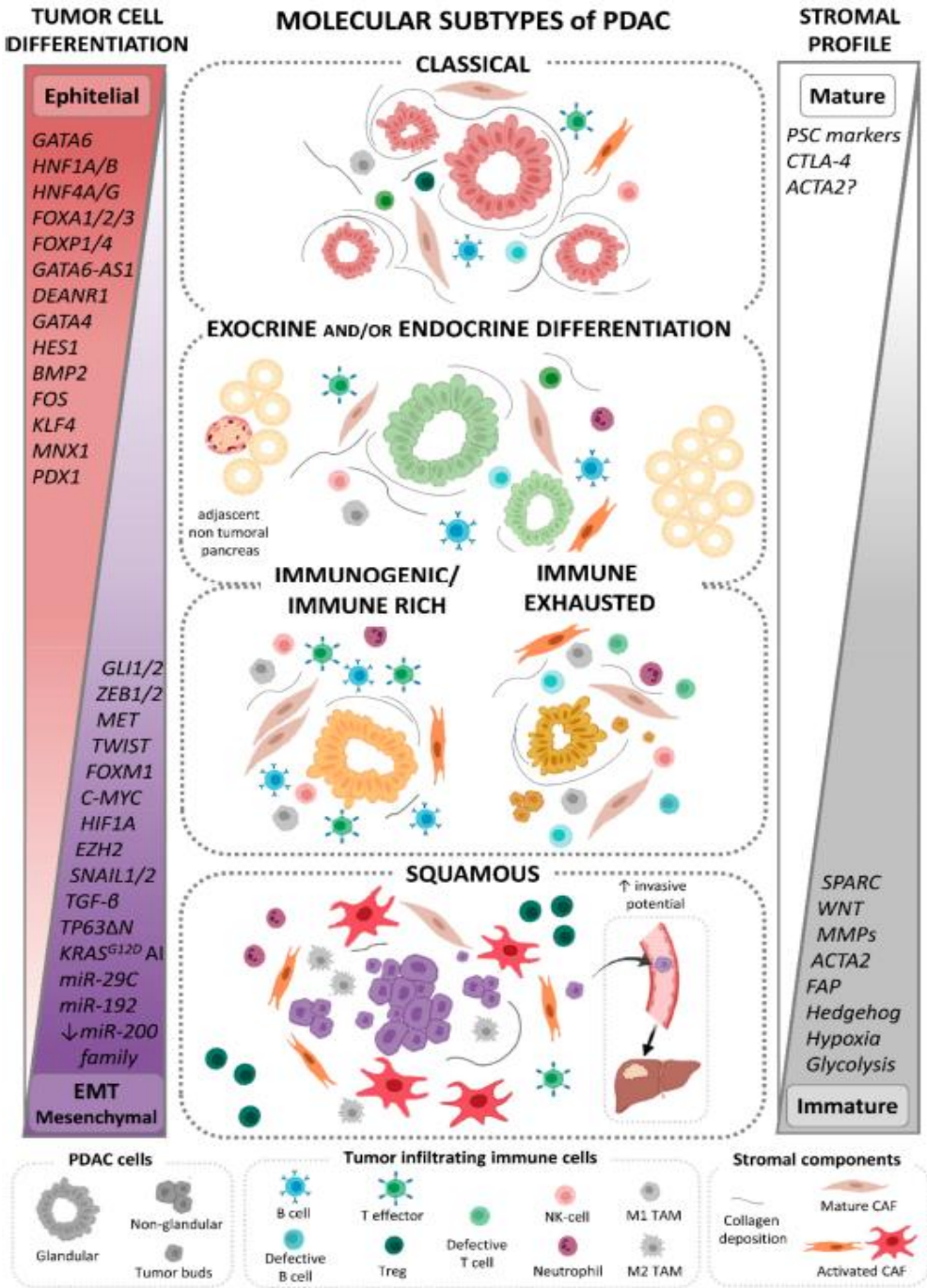
TUMOR CELL DIFFERENTIATION
MOLECULAR SUBTYPES of PDAC
STROMAL PROFILE
Ephitelial
GATA6
HNF1A/B
HNF4A/G
FOXA1/2/3
FOXP1/4
GATA6-AS1
DEANR1
GATA4
HES1
BMP2
FOS
KLF4
MNX1
PDX1
CLASSICAL
EXOCRINE AND/OR ENDOCRINE DIFFERENTIATION
adjascent non tumoral pancreas
IMMUNOGENIC/ IMMUNE RICH
IMMUNE EXHAUSTED
SQUAMOUS
↑ invasive potential
GLI1/2
ZEB1/2
MET
TWIST
FOXM1
C-MYC
HIF1A
EZH2
SNAIL1/2
TGF-β
TP63ΔN
KRASG12D AI
miR-29C
miR-192
↓miR-200 family
EMT
Mesenchymal
Mature
PSC markers
CTLA-4
ACTA2?
SPARC
WNT
MMPs
ACTA2
FAP
Hedgehog
Hypoxia
Glycolysis
Immature
PDAC cells
Glandular
Non-glandular
Tumor buds
Tumor infiltrating immune cells
B cell
T effector
Defective T cell
NK-cell
M1 TAM
Defective B cell
Treg
Neutrophil
M2 TAM
Stromal components
Collagen deposition
Mature CAF
Activated CAF

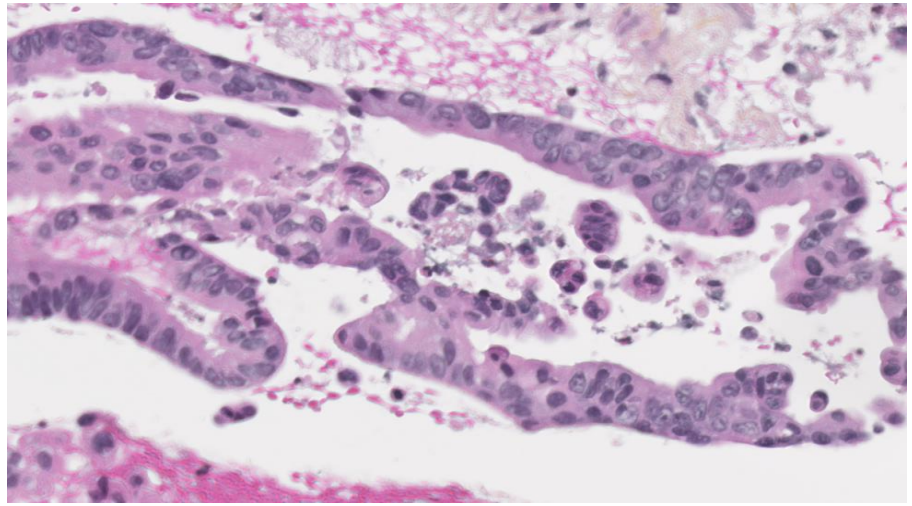

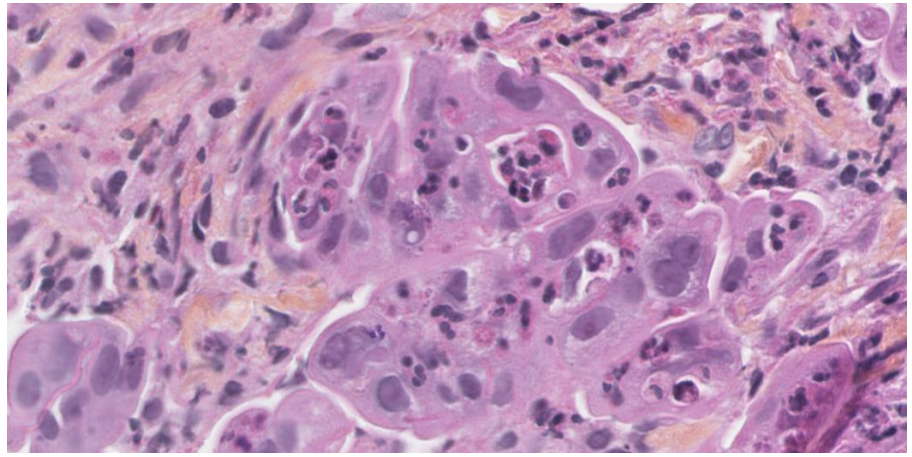

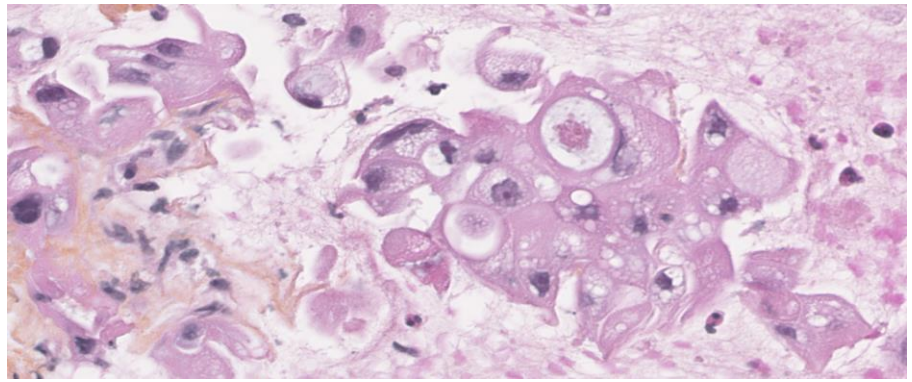

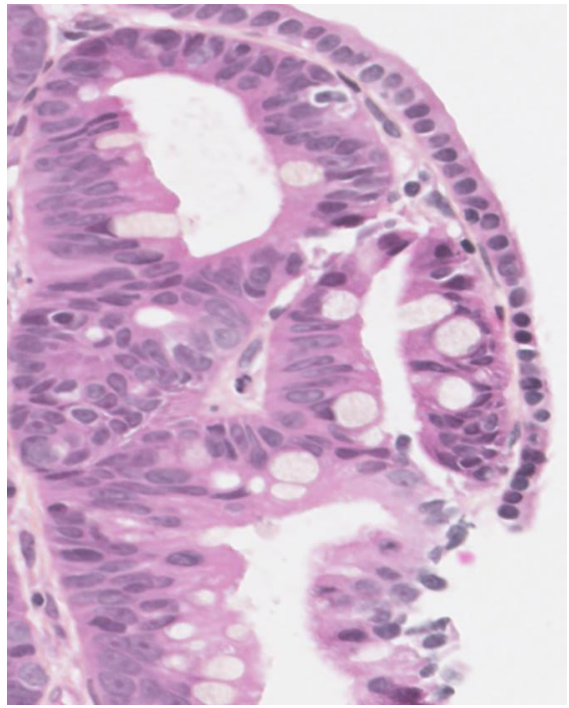

# Dg dif ADK canalaire PEE = Pancréatite chronique

- Si contexte clinique +++ mais PCC facteur de risque d'ADK
  - Critères architecturaux
  - Difficile sur PEE+++
  - Sensibilité faible FNA.A:
    - 65% vs 91% sans PCC
  - Faux positifs
    - Accepter atypies modérées dans un contexte inflammatoire
- Pas d'aide de l'immunohistochimie

**Table 1 – Eight features supportive of the diagnosis of ductal adenocarcinoma.[6]**

| Ductal adenocarcinoma | Reactive glands |
|---|---|
| Haphazard arrangement of the glands | Lobular arrangement of glands |
| Perineural invasion | Neuroendocrine cells can abut nerves |
| Vascular invasion | Not seen |
| Gland immediately adjacent to a muscular artery | Glands separated from muscular vessels by acinar cells or by orderly rounded connective tissue |
| Luminal necrosis | Can have polymorphonuclear leukocytes, but not epithelial necrosis |
| Incomplete lumina | Epithelial cells form a complete ring around lumina |
| Four-to-one rule | Nuclei in a single gland vary by less than four to one |
| "Naked" glands in fat | Glands in fat have associated connective tissue |

**Table 2 – Immunolabeling characteristics of ductal adenocarcinoma[6] and the associated desmoplastic stroma.**

| | |
|---|---|
| In the neoplastic cells | |
| Cytokeratins | CK7, 8, 18, 19, and ±20 |
| Mucins | MUC1, MUC3, MUC4, and MUC5AC |
| Cancer markers | CEA, CA19-9, B72.3, DUPAN-2, and CA125 |
| Mutational markers | SMAD4 (lost) and TP53 (labeling gained) |
| Others | Mesothelin, PSCA, claudin 4, S-100A4, A-100A6, and S-100P |
| In the stromal cells | |
| SPARC and fibronectin | |
| Inflammatory cells | CD3, CD4, CD8, Tregs (FOXP-3), CD20, and MAC387 |

# PEE – Pancréatite chronique

- Forme pseudo-tumorale
- PCC :
    - Cellules inflammatoires
    - Cellules canalaires
    - Débris d'aspect biliaire
    - Concrétions protéiques

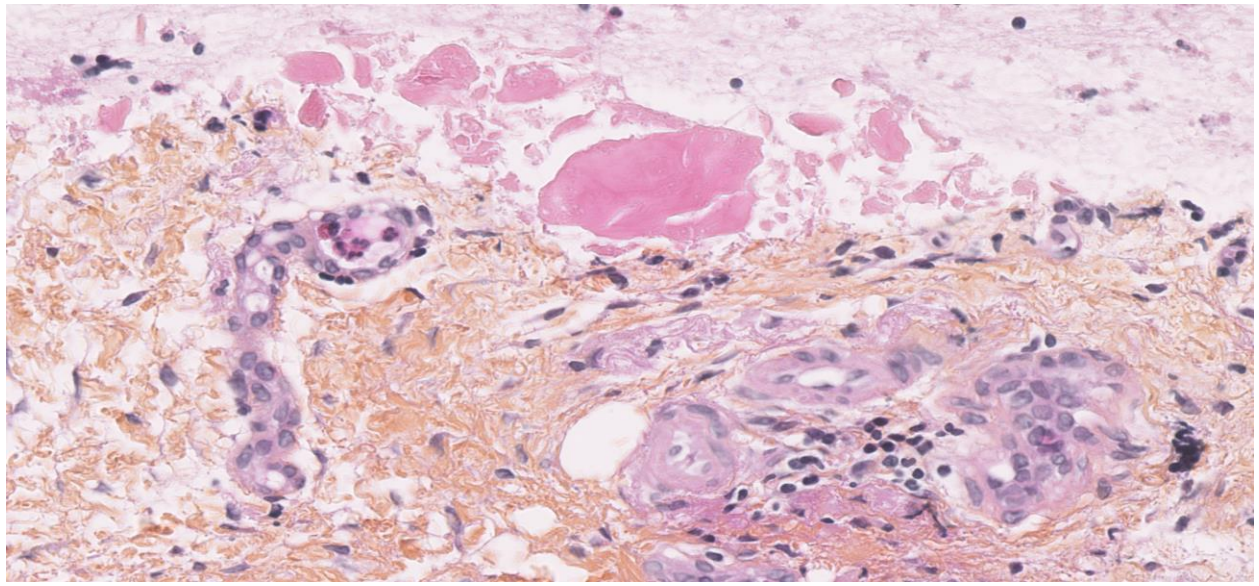

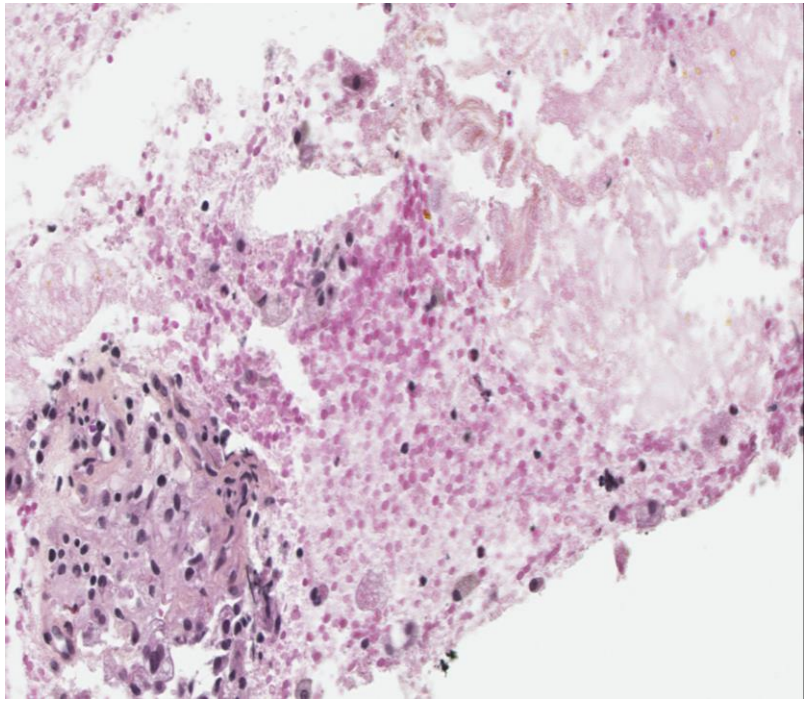

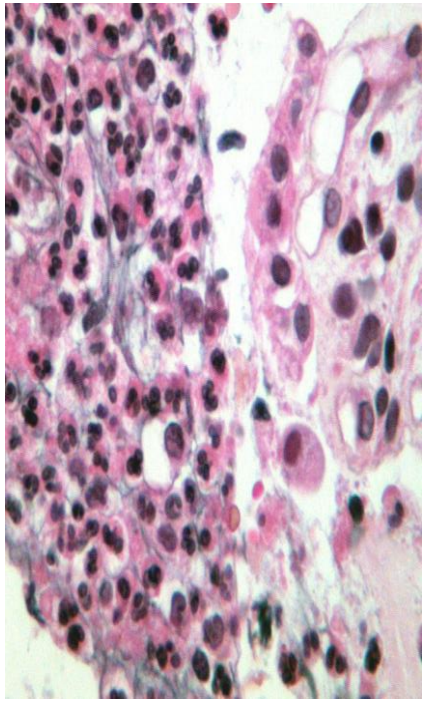

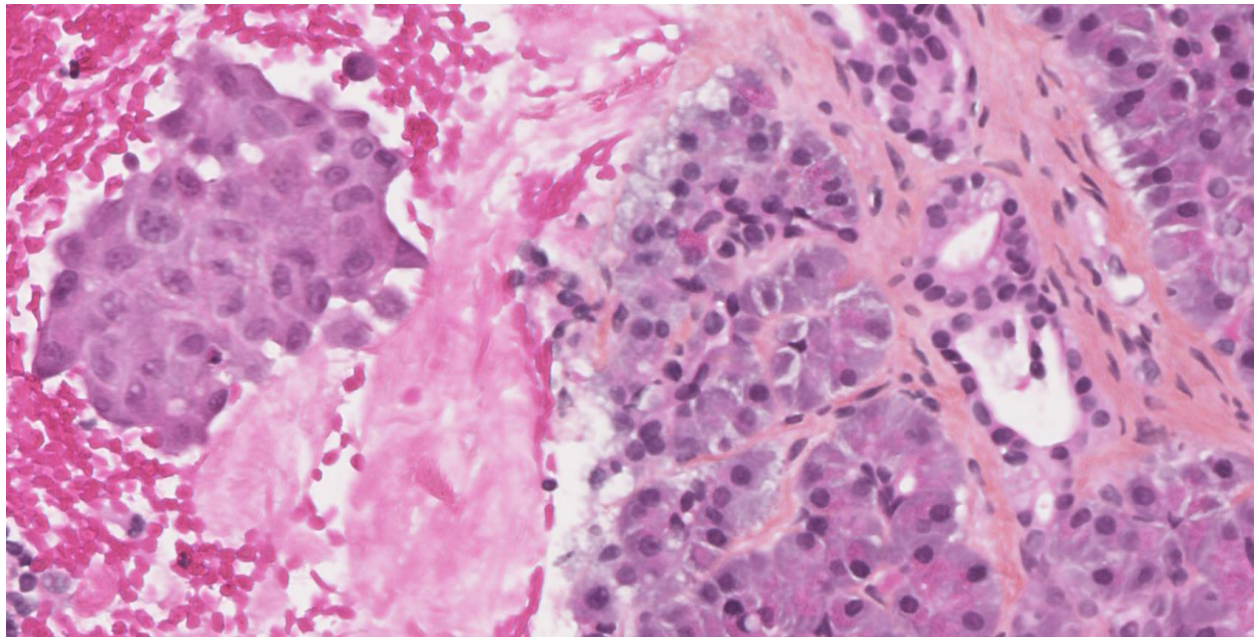

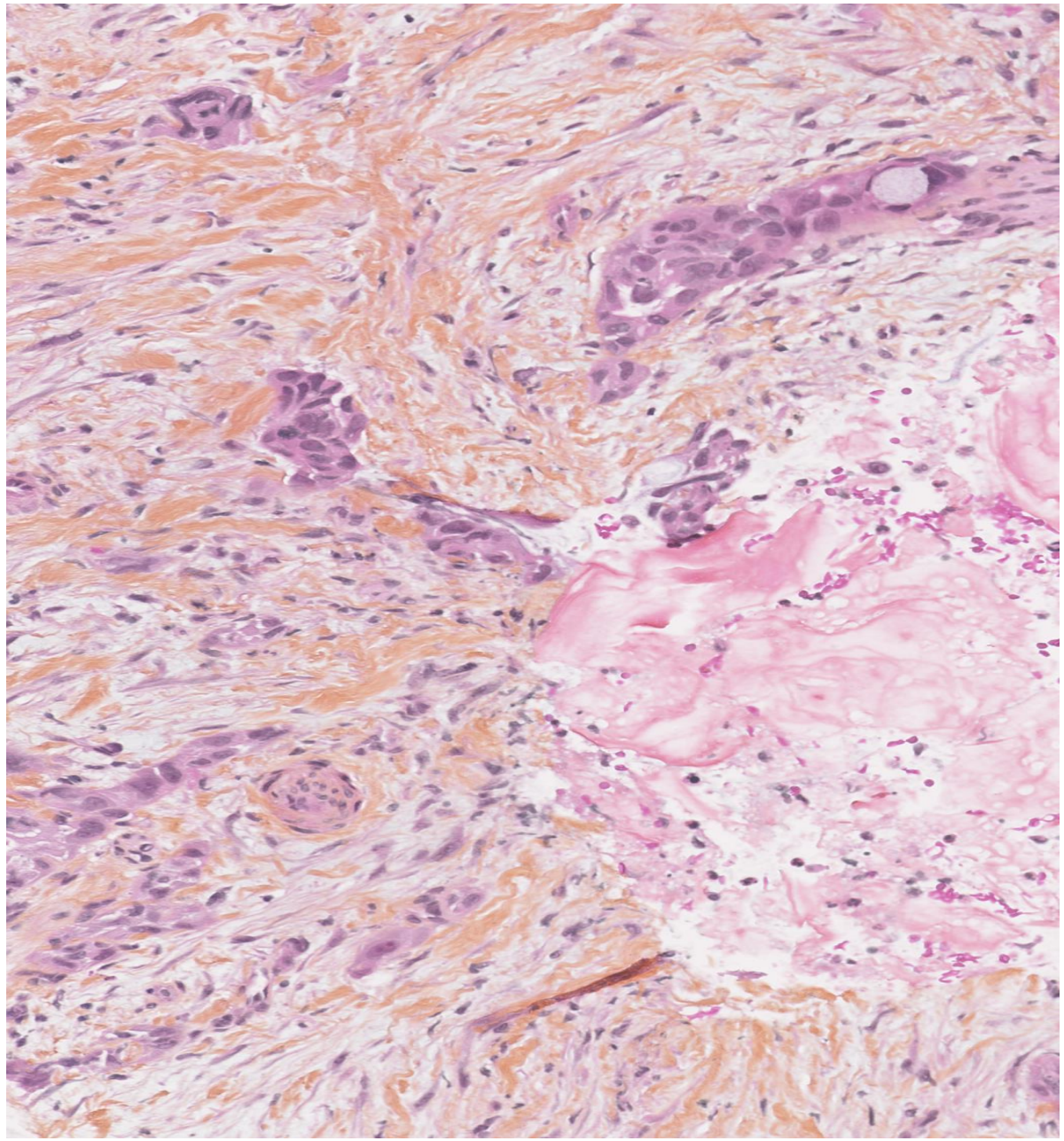

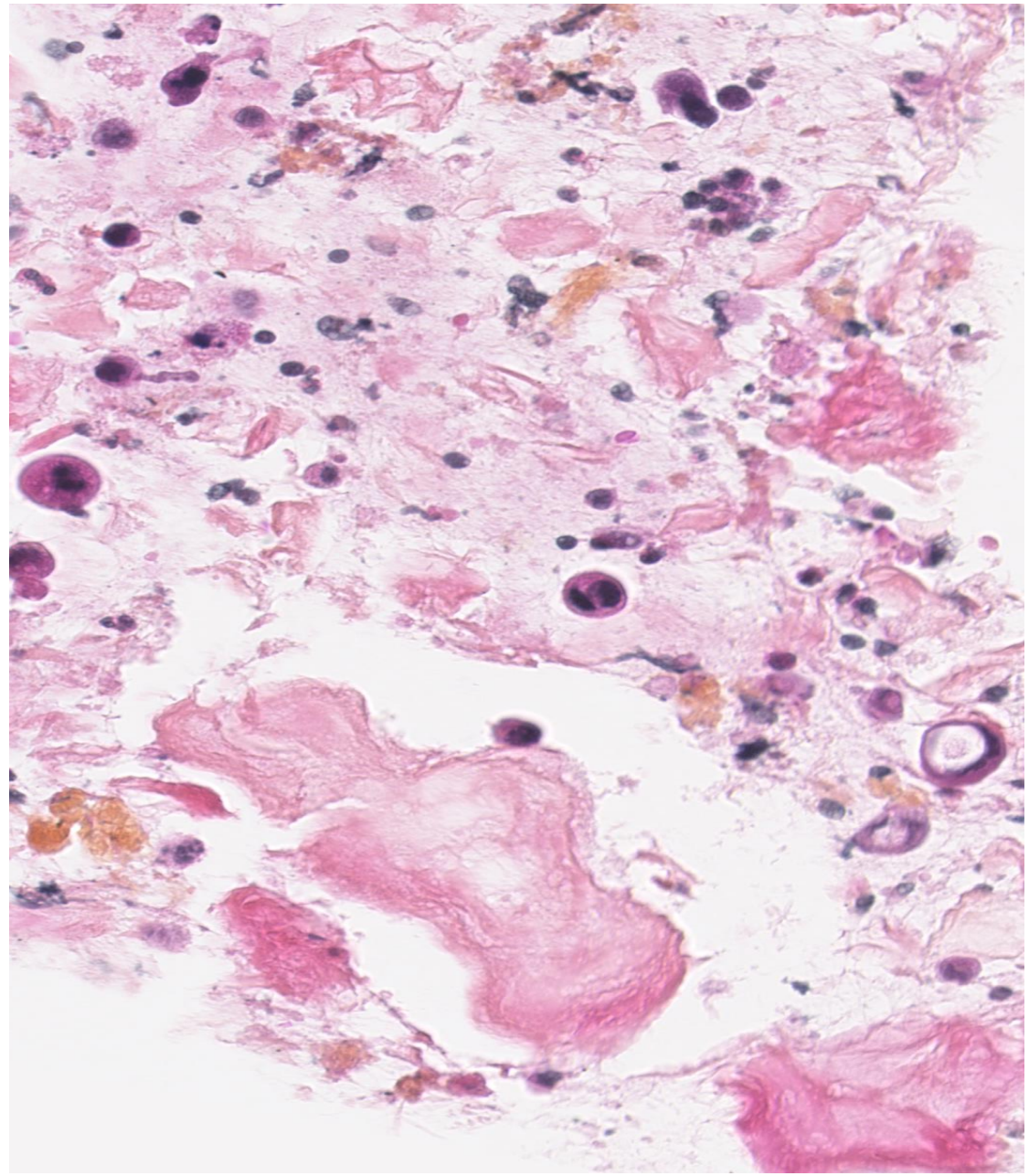

# PEE – Pancréatite auto-immune

- Dg devient possible :
  - Type I : IgG4 +
  - Type 2 : neutrophilique +/-
- 99% travail = absence de malignité !
- Après … morpho et contexte clinique +++
  - Plasmocytes
  - PN

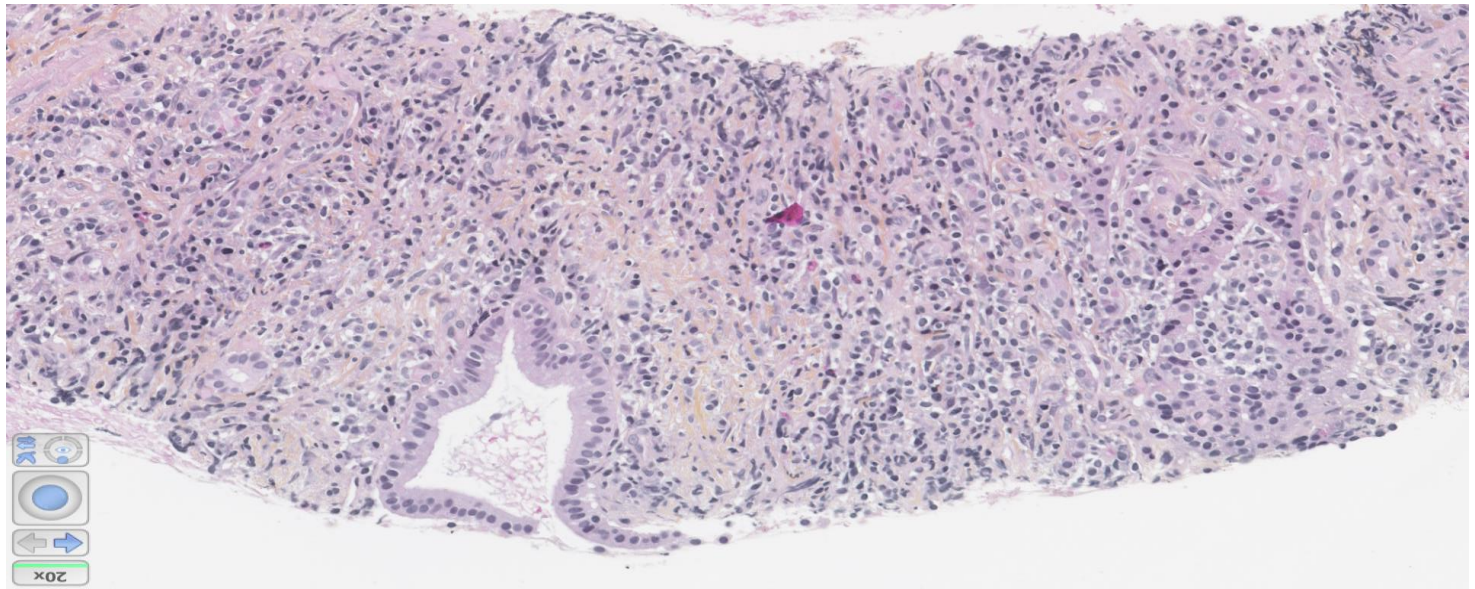


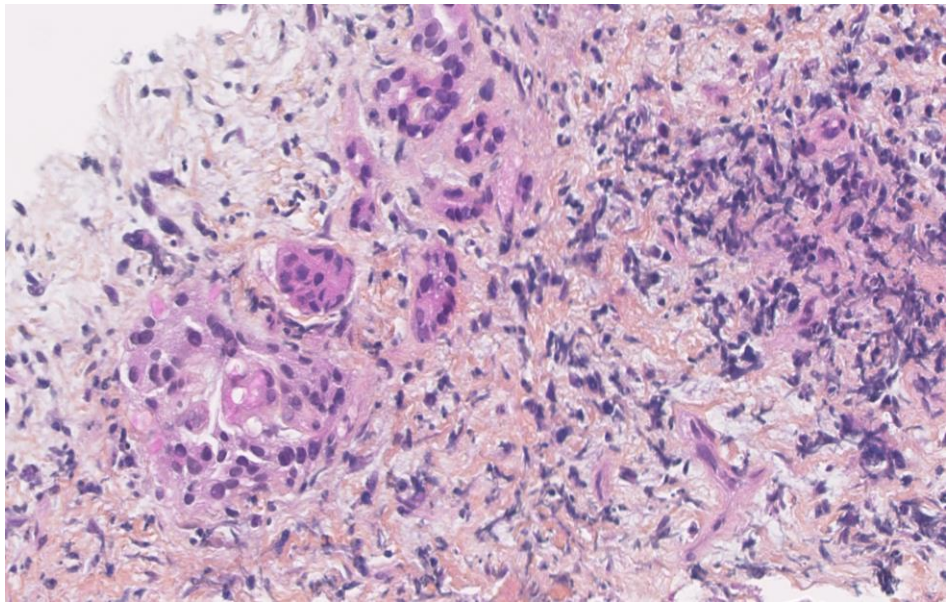

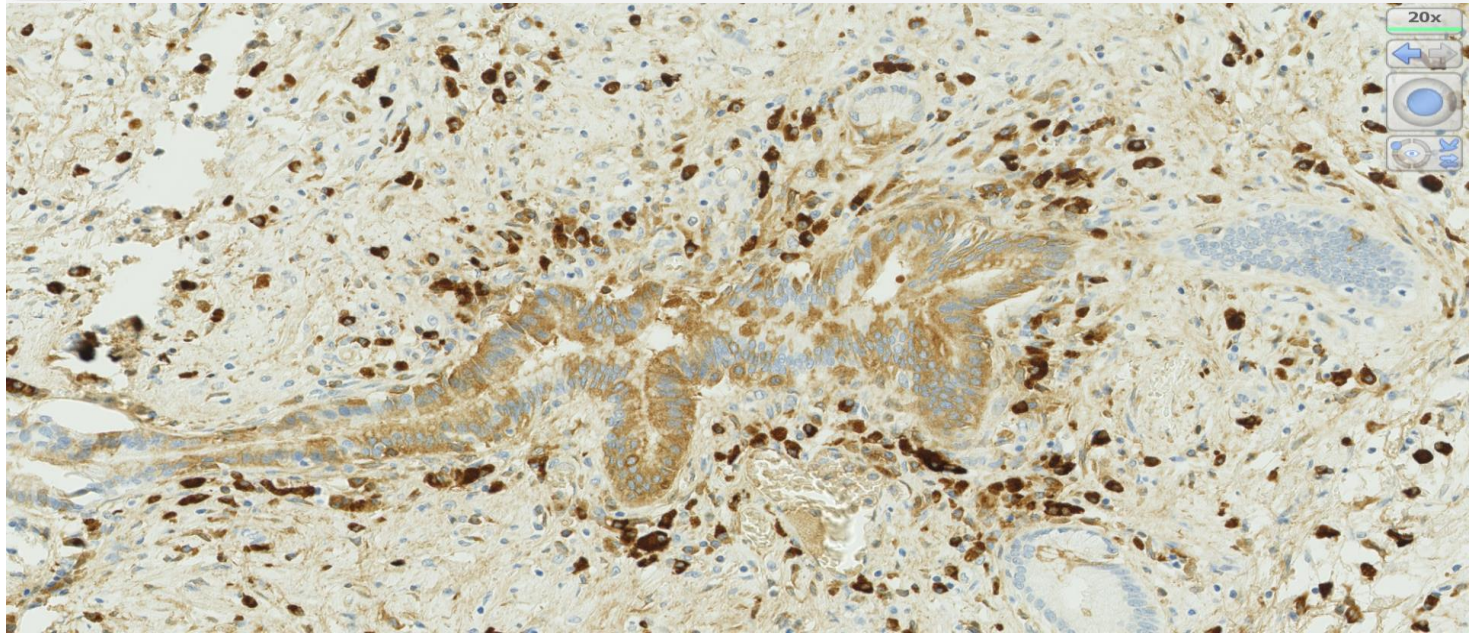

# Démarche dg des T solides pancréatiques

**Tumeur solide**

**> 90%**

**Glandes tumorales +/- mucosécrétion +/- stroma abondant**

**Adénocarcinome canalaire**

**Densité cellulaire élevée avec peu ou pas de stroma**

**Différenciation tumorale prédominante**

**Acinaire**

**BCL10**

**Carcinome à cellules acinaires**

*pancréatoblastome*

**Neuro-endocrine**

**Chromogranine, synaptophysine, Ki67**

**Tumeur neuro-endocrine**

**Indéfinie**

**Beta-caténine**

**MUC6**

**Tumeur solide et pseudo-papillaire**

**Cystadénome séreux**

**Inhabituelle pour la localisation**

**Autres ac**

**Métastase**

# Densité cellulaire élevée avec peu ou pas de stroma

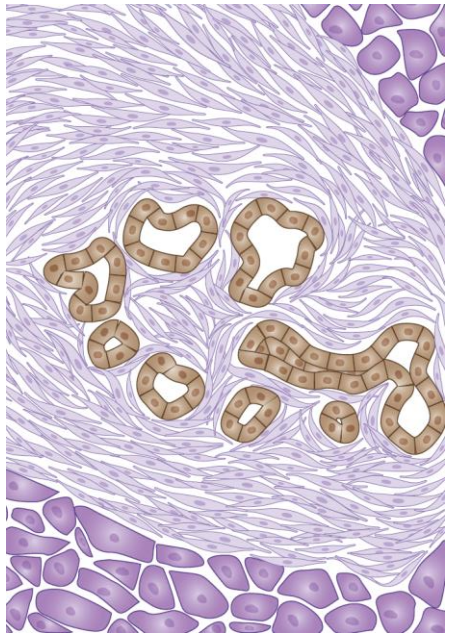

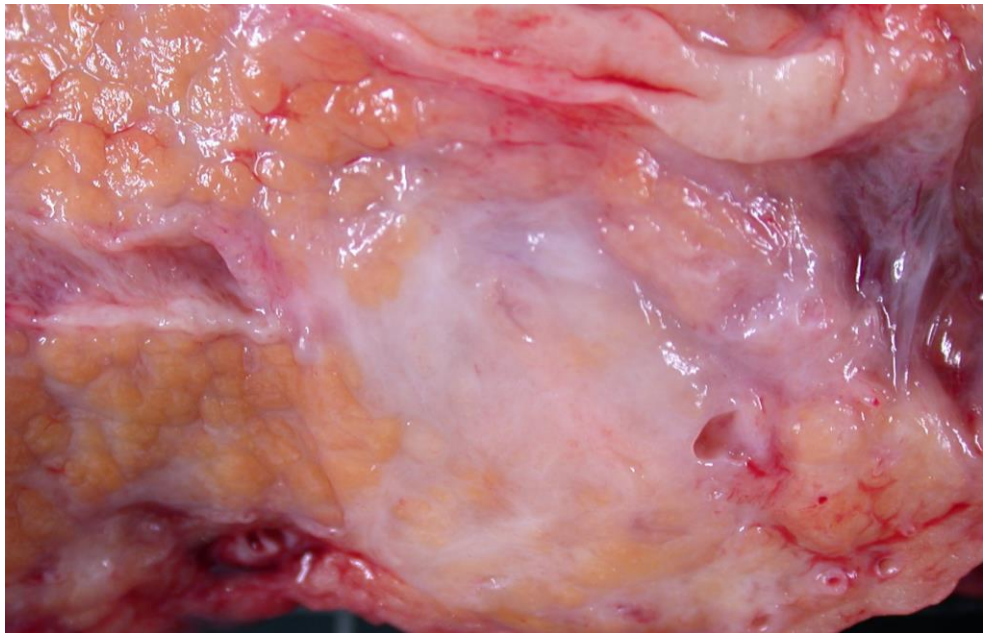

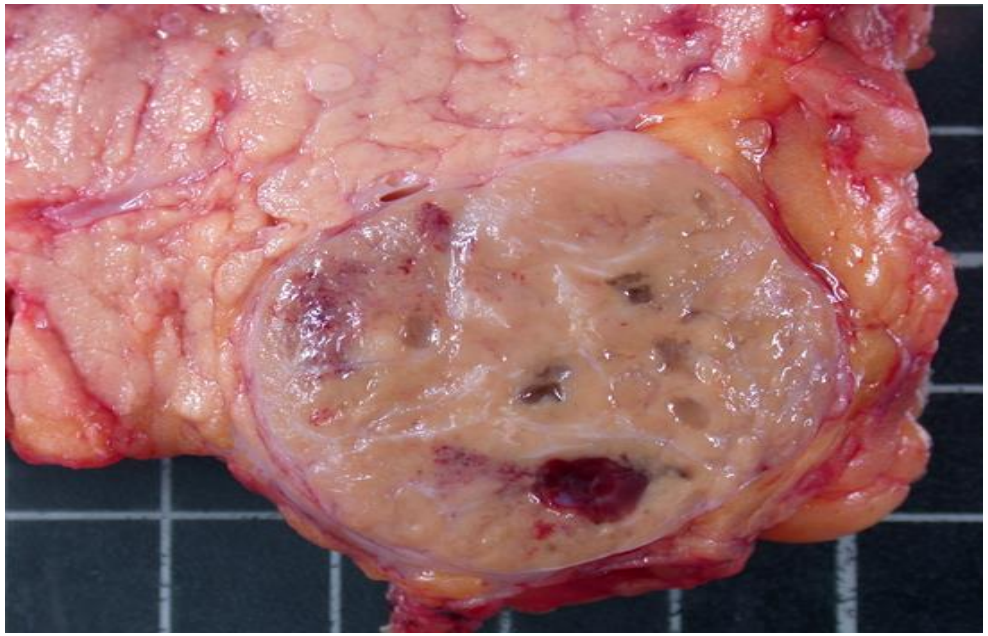

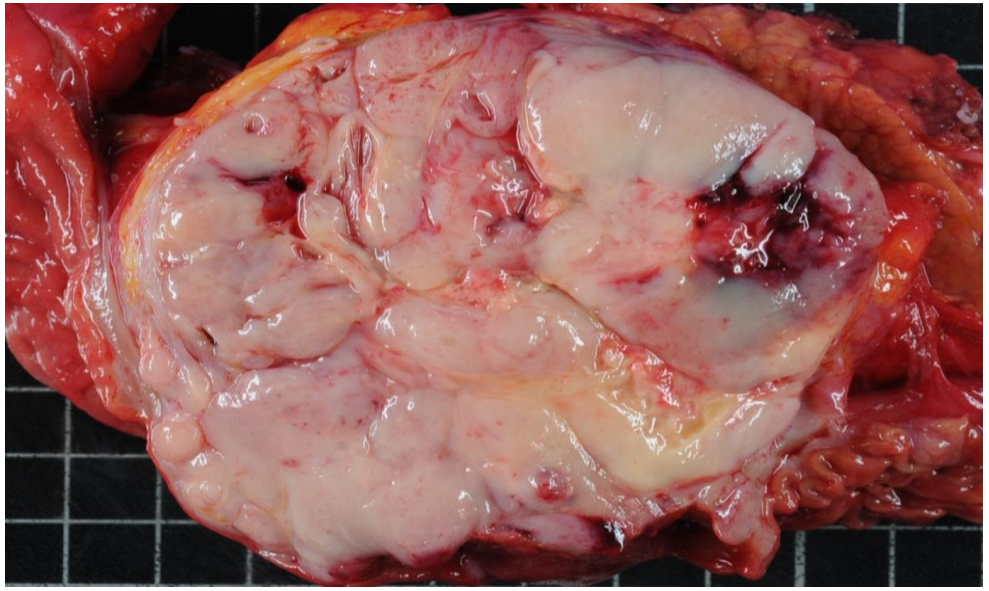

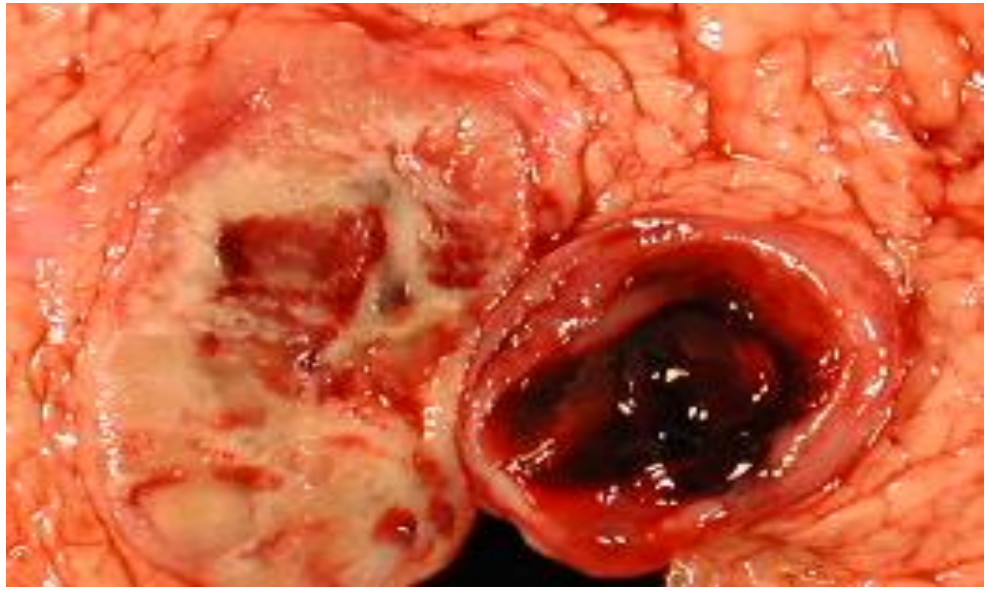

# PEE – Tumeurs solides : TEP

- Sensibilité inférieure à l'ADK :
  - 52-81% vs >85-93% en raison :
    - Caractère hémorragique
      - T hypervascularisée
    - Caractère kystique

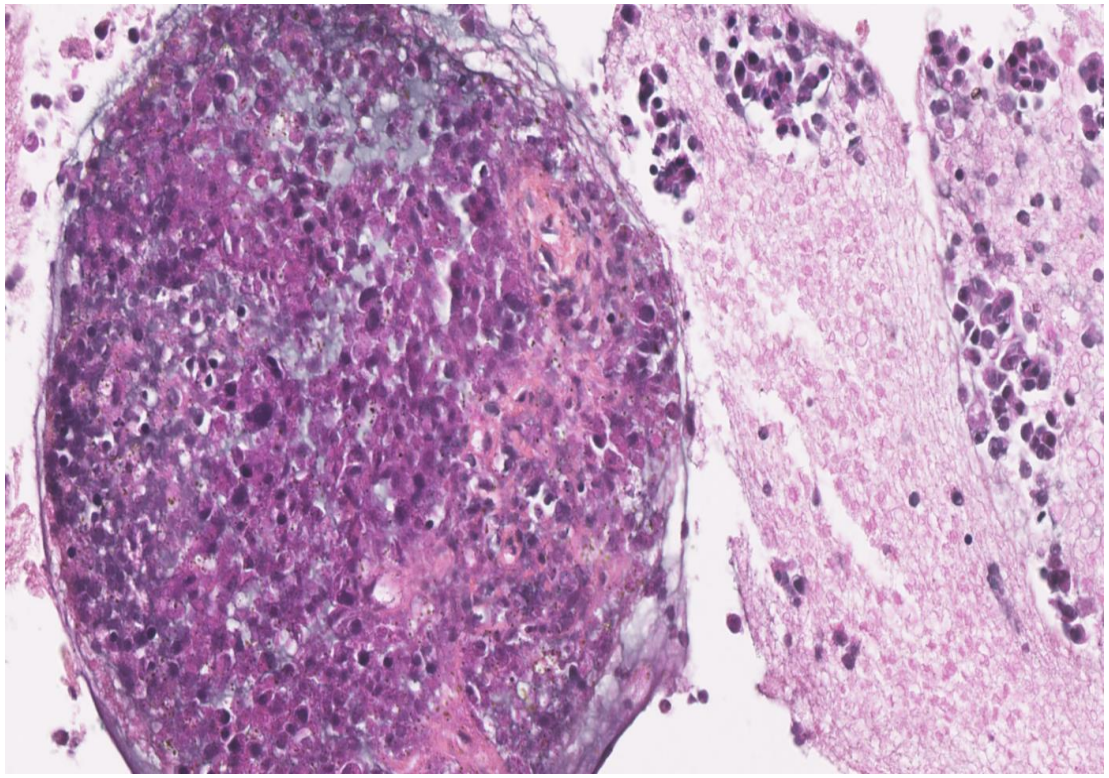

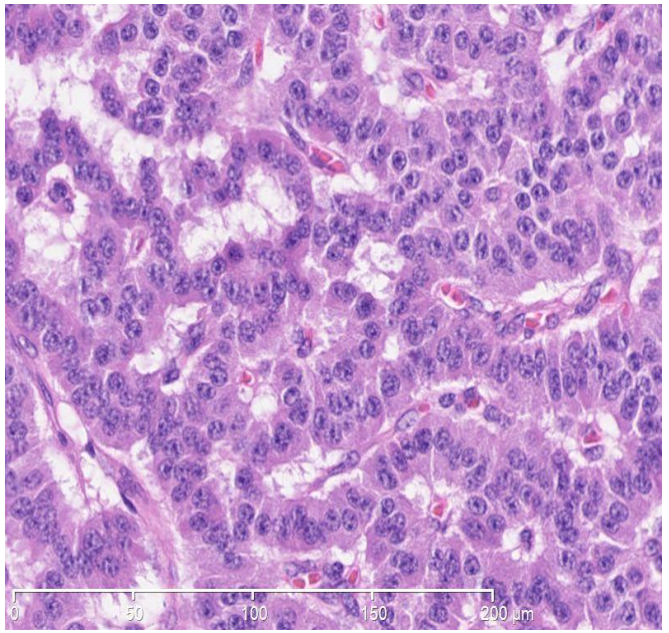


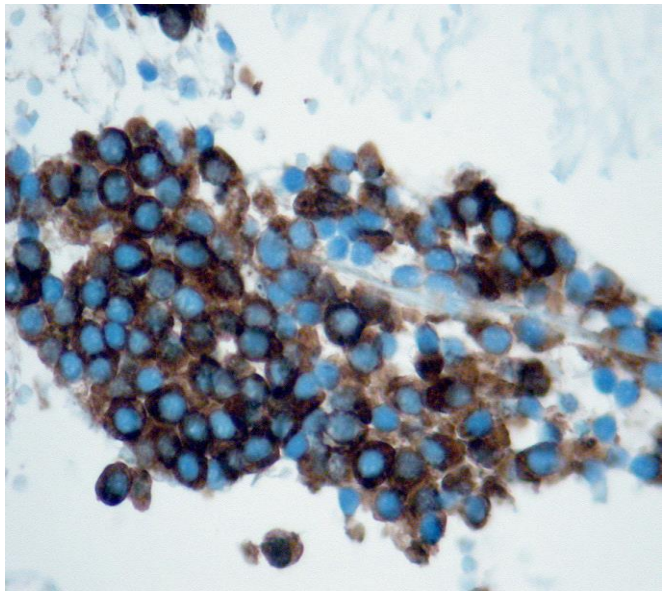

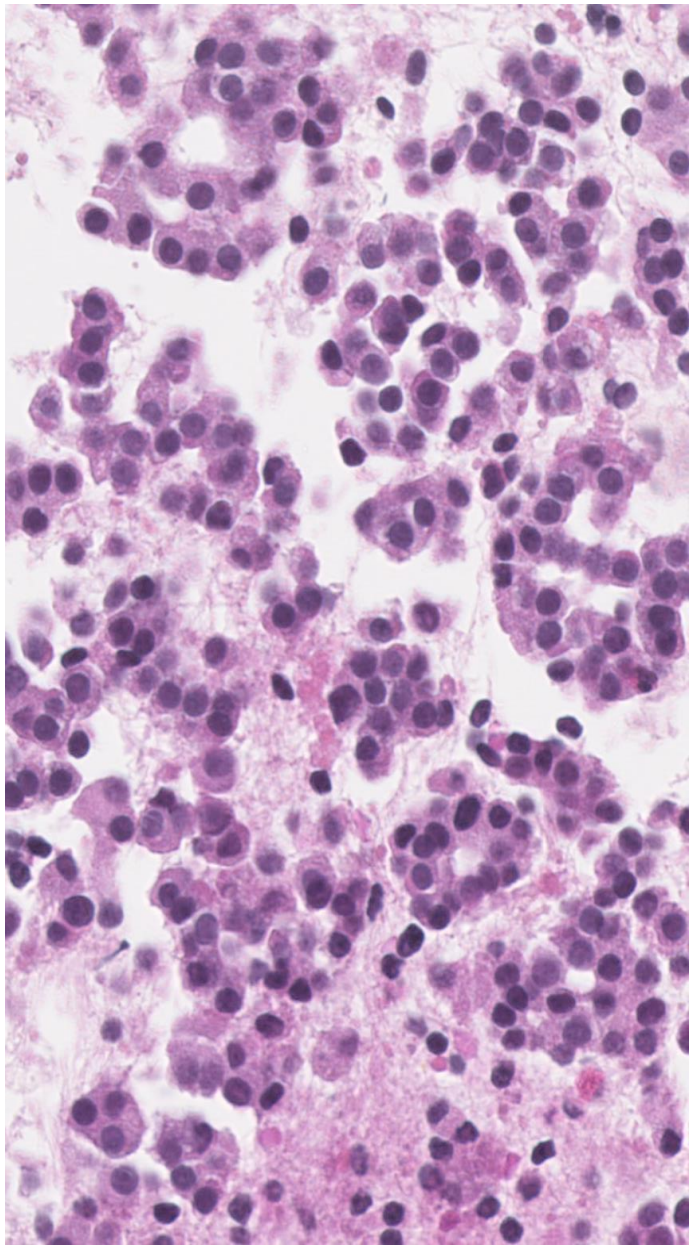

# PEE – Tumeurs solides : TEP

>90%

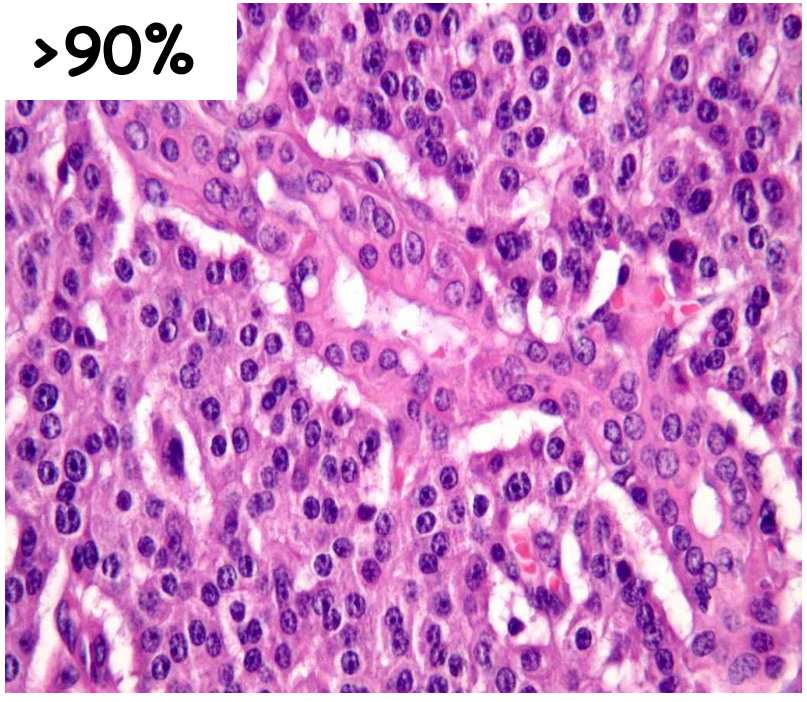

Tumeur neuro-endocrine bien différenciée

10%

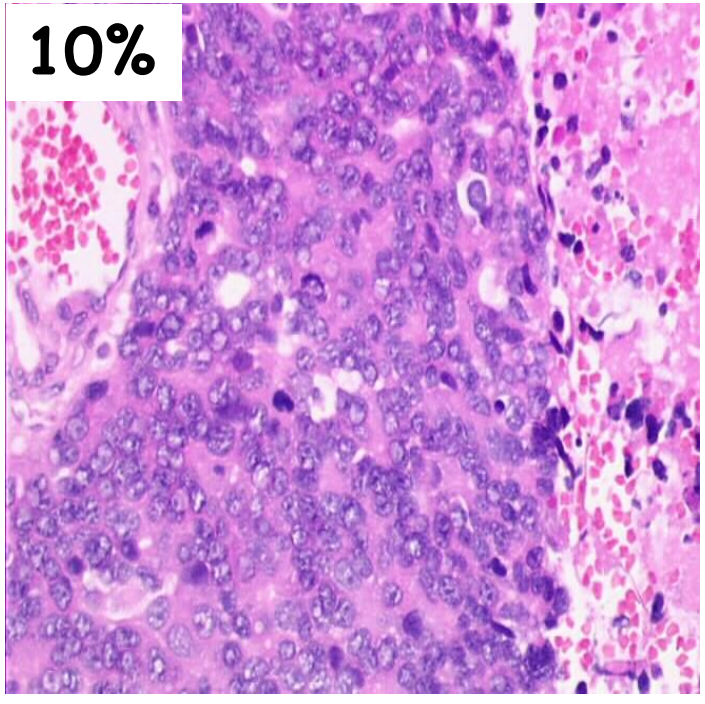

Carcinome neuro-endocrine peu différencié

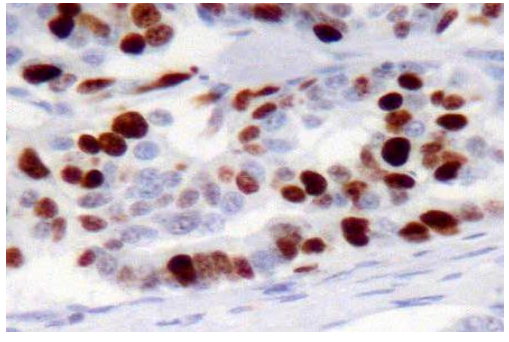

Table 1. WHO 2019 classification for gastroenteropancreatic NENs[9]

| Morphology | Grade | Mitotic count (2 $mm^2$)[a] | Ki-67 Index (%)[b] |
|---|---|---|---|
| Well-differentiated NETs | G1 | <2 | <3 |
| Well-differentiated NETs | G2 | 2–20 | 3–20 |
| Well-differentiated NETs | G3 | >20 | >20 |
| Poorly-differentiated NECs<br>• Small-cell<br>• Large-cell | G3 | >20 | >20 |
| MiNEN | | | |
| Tumour-like lesions | | | |

**Corrélation Grade ponction/chirurgie :**
**- Bonne pour G1**
**- Sous évaluation de G2 si moins de 1000 cellules**

*Abi Raad, 2020*

# PEE – Tumeurs solides : Carcinome à cellules acinaires

- Tumeurs rares : 1%
- Souvent volumineuses solides mais des formes :
  - Kystiques
  - Et/ou à Extension endo-canalaire
- Signes de différenciation acinaires +/- moins nets
- IHC : Bcl10 +++
  - Homologies des portions c-term de BCL10 avec CEH
- Dg dif : TNE ou CNE

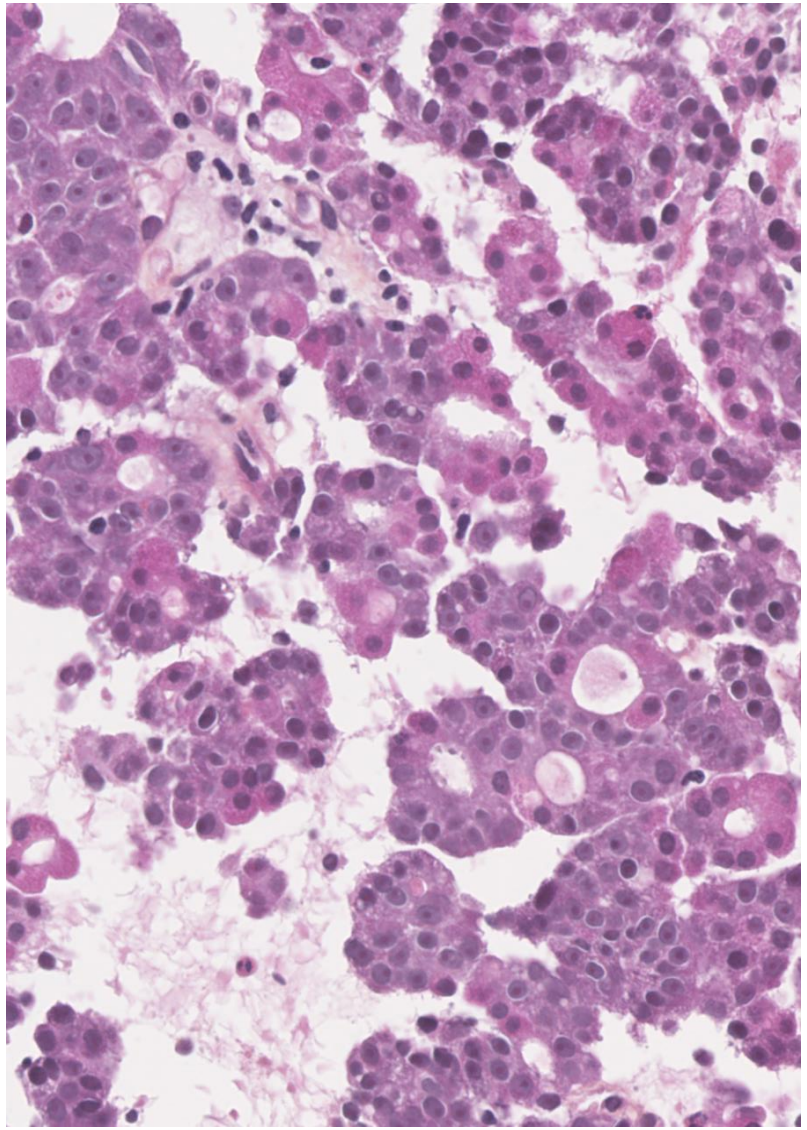

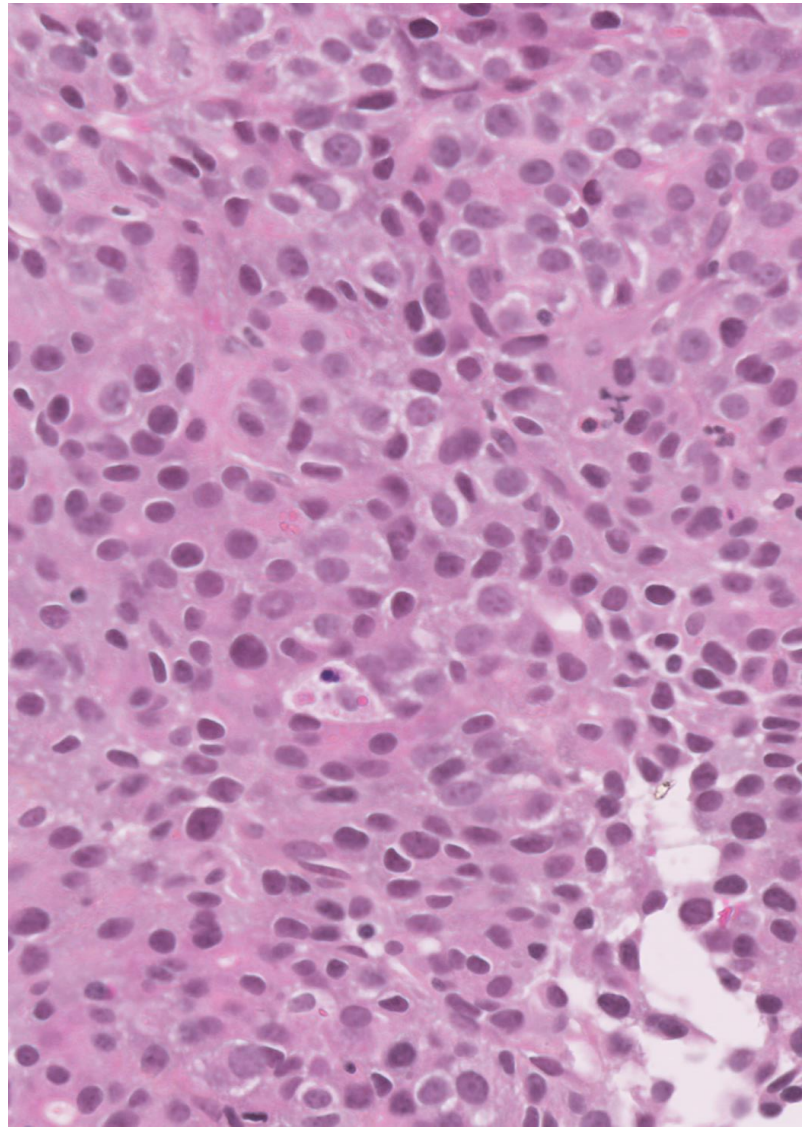

TABLE 4. Immunohistochemical Findings

| | ACCs | MANECs | Total |
|---|---|---|---|
| Chromogranin A* | 0/49† | 12/12 (100%) | 12/61 (20%) |
| Synaptophysin* | 0/49† | 12/12 (100%) | 12/61 (20%) |
| Trypsin | 46/48 (96%) | 11/12 (92%) | 57/60 (95%) |
| COOH-terminal BCL10 | 40/47 (85%) | 11/12 (92%) | 51/59 (86%) |
| CEL | 29/32 (91%) | 8/9 (89%) | 37/41 (90%) |
| Amylase | 2/25 (8%) | 1/8 (12%) | 3/33 (9%) |
| Lipase | 9/30 (30%) | 1/9 (11%) | 10/39 (26%) |
| p53 | 6/28 (21%) | 4/9 (44%) | 10/37 (27%) |
| CK19 | 29/34 (85%) | 8/9 (89%) | 37/43 (86%) |
| CK7 | 25/28 (89%) | 2/9 (22%) | 27/37 (73%) |
| β-Catenin | | | |
| Membrane | 24/25 (96%) | 5/8 (62%) | 29/33 (88%) |
| Nuclear | 1/25 (4%) | 3/8 (37%) | 4/33 (12%) |
| PDX1 | 21/24 (87%) | 8/8 (100%) | 29/32 (91%) |

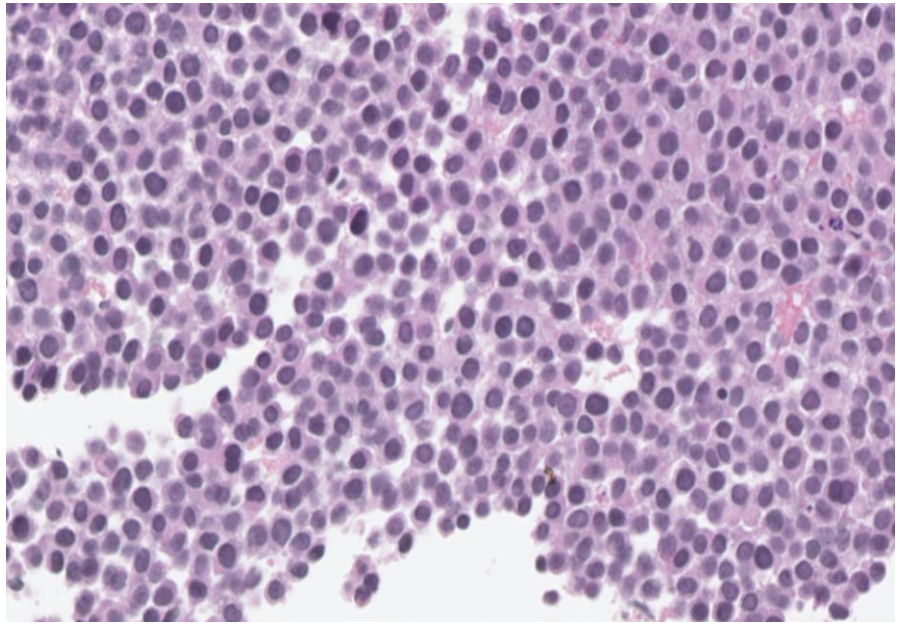
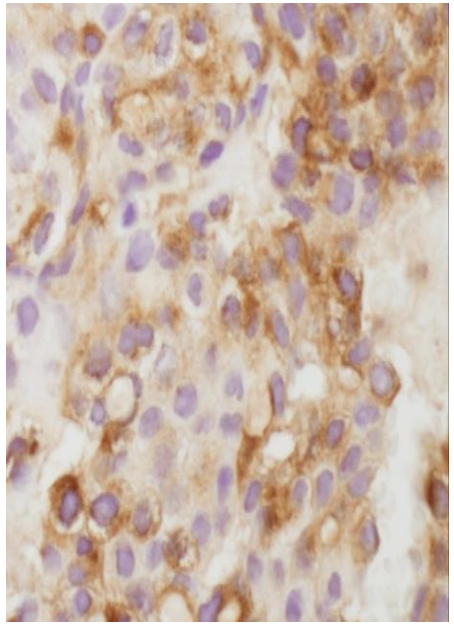
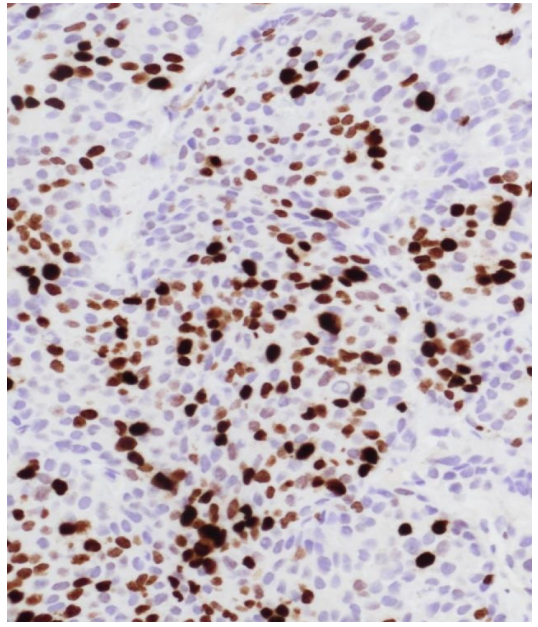
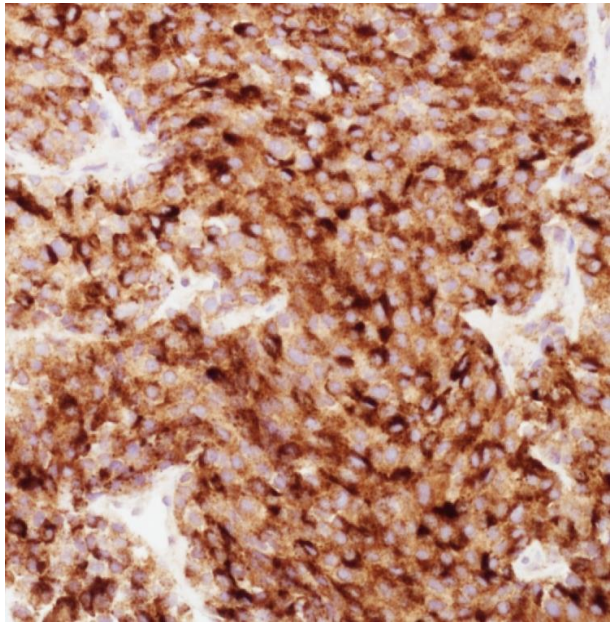

# PEE – Tumeurs solides : TS pseudo-papillaire

- Femme jeune +++
- Tumeur :
  - Kystique
  - Solide
  - Solide et kystique !
- Beta-caténine +
  - Synapto + (20-50%)

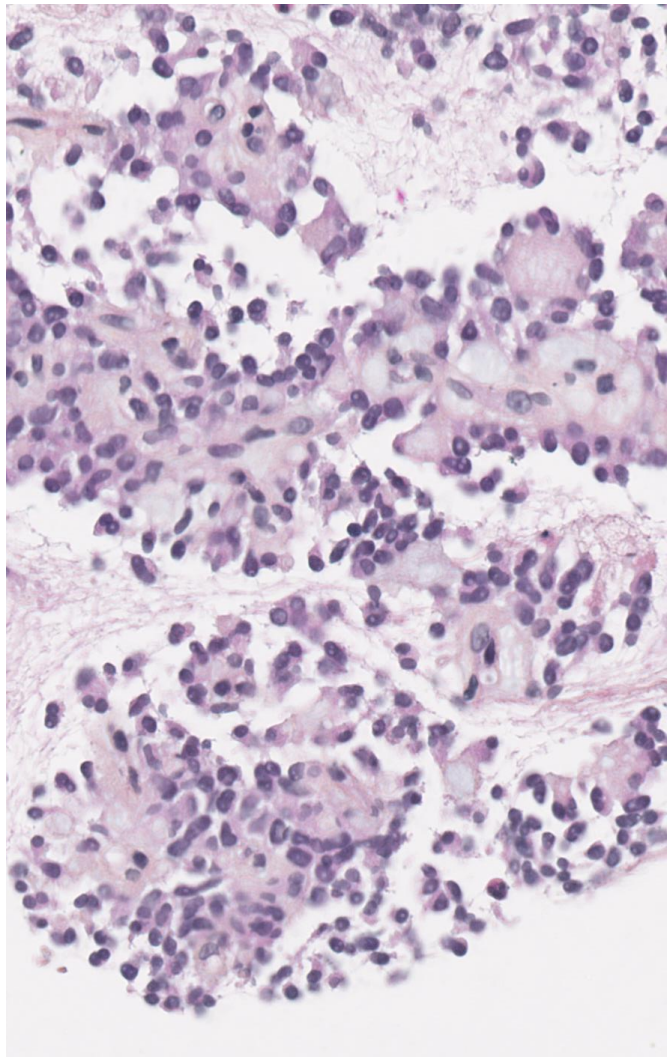

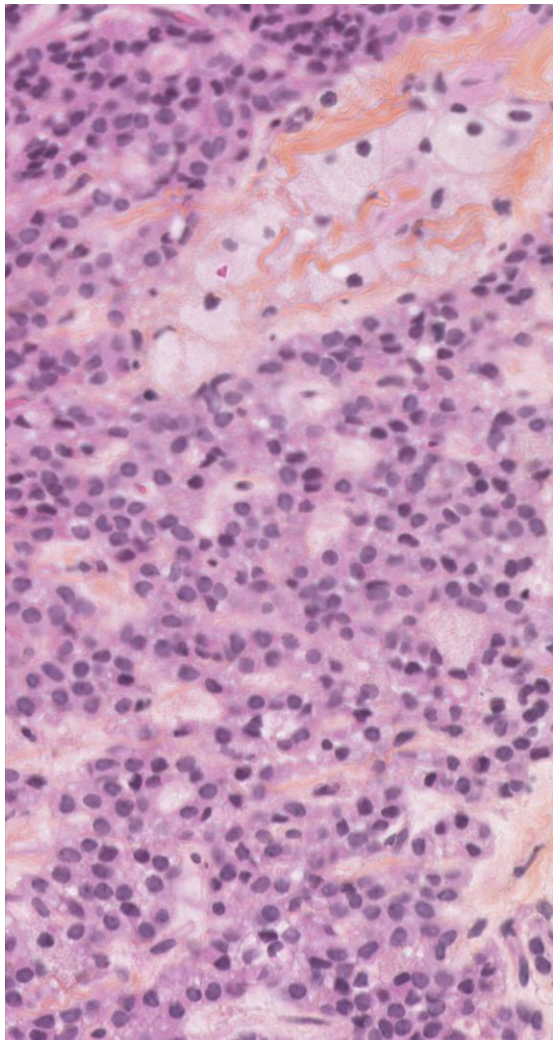

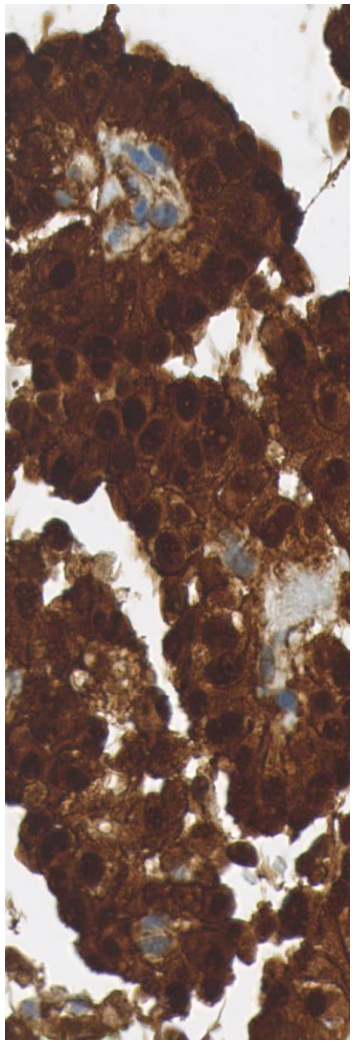

# PEE – Tumeurs solides … qui n'en sont pas !

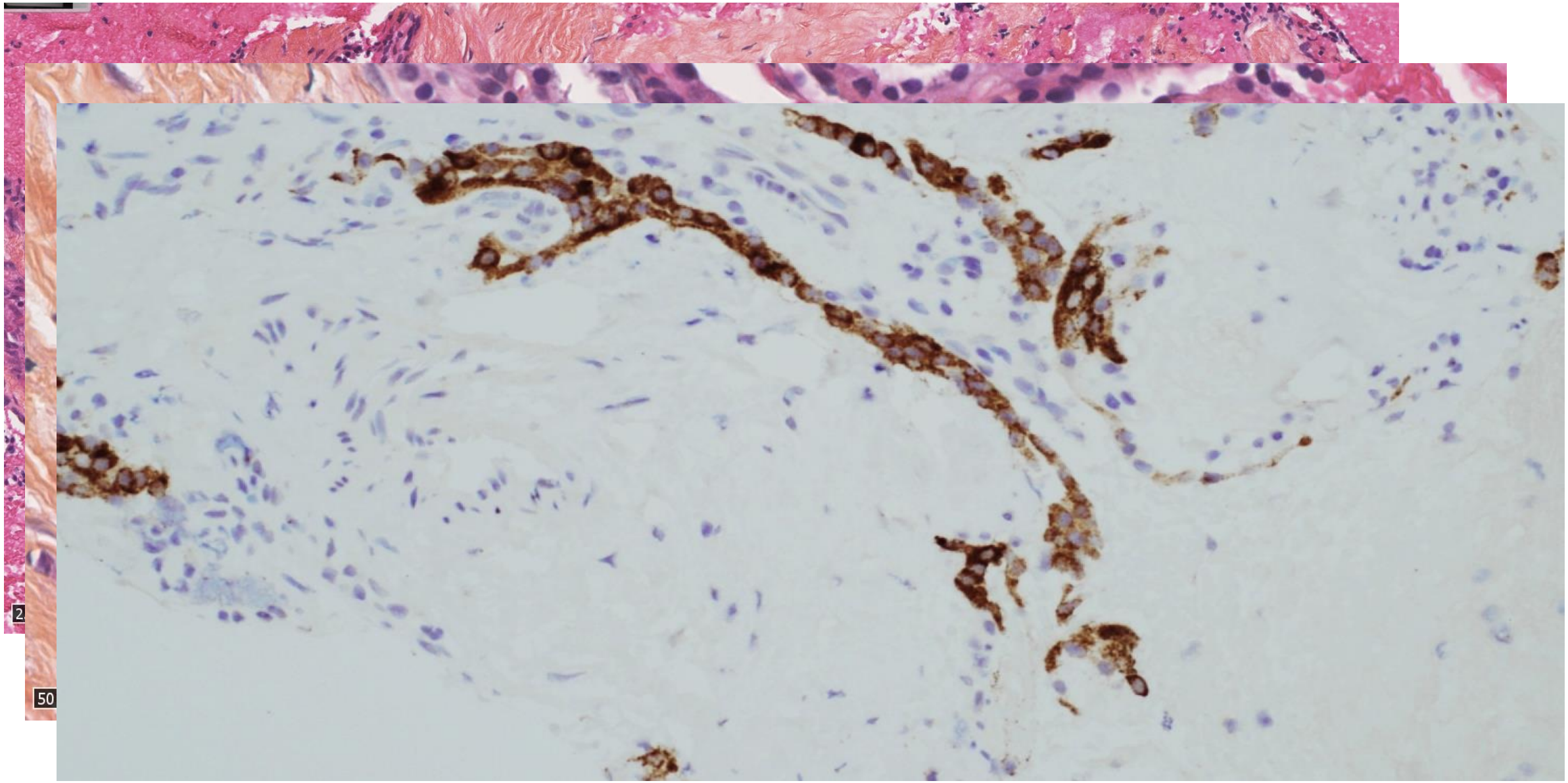

# PEE - Tumeurs solides pancréatiques … qui ne sont pas primitives !

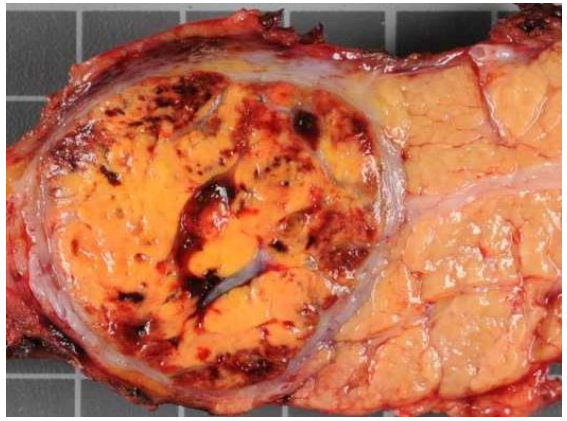

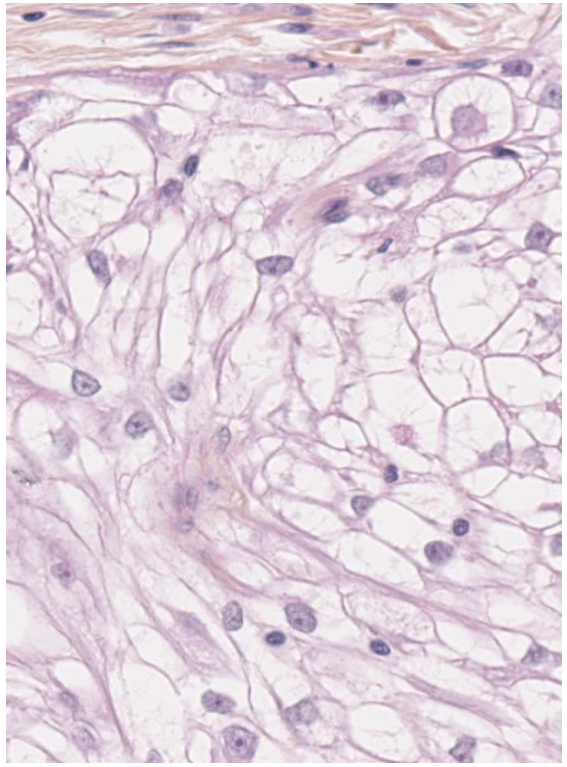

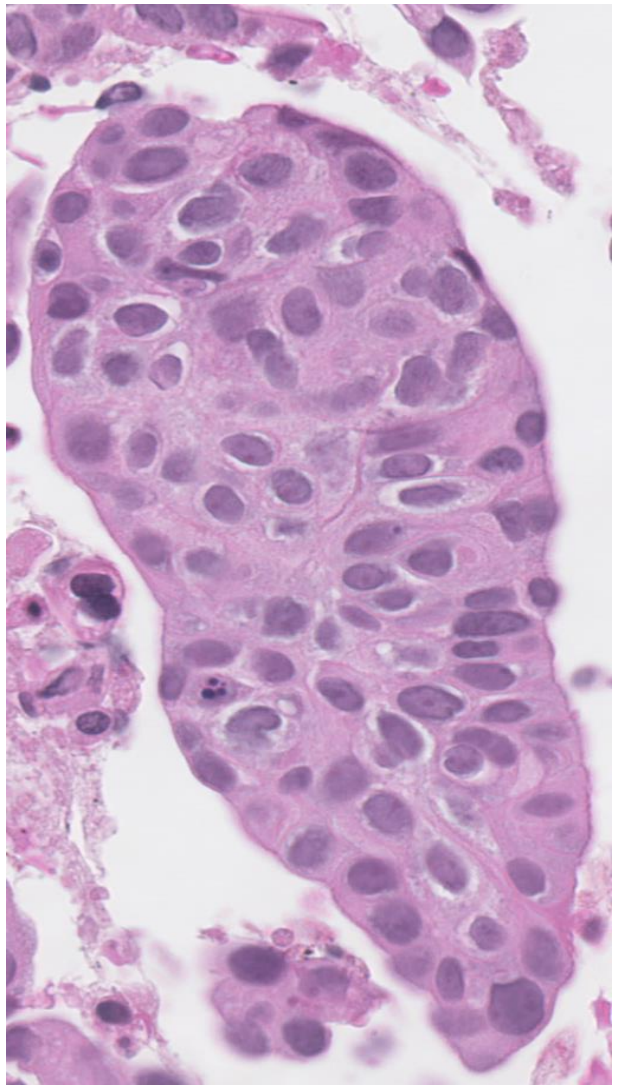

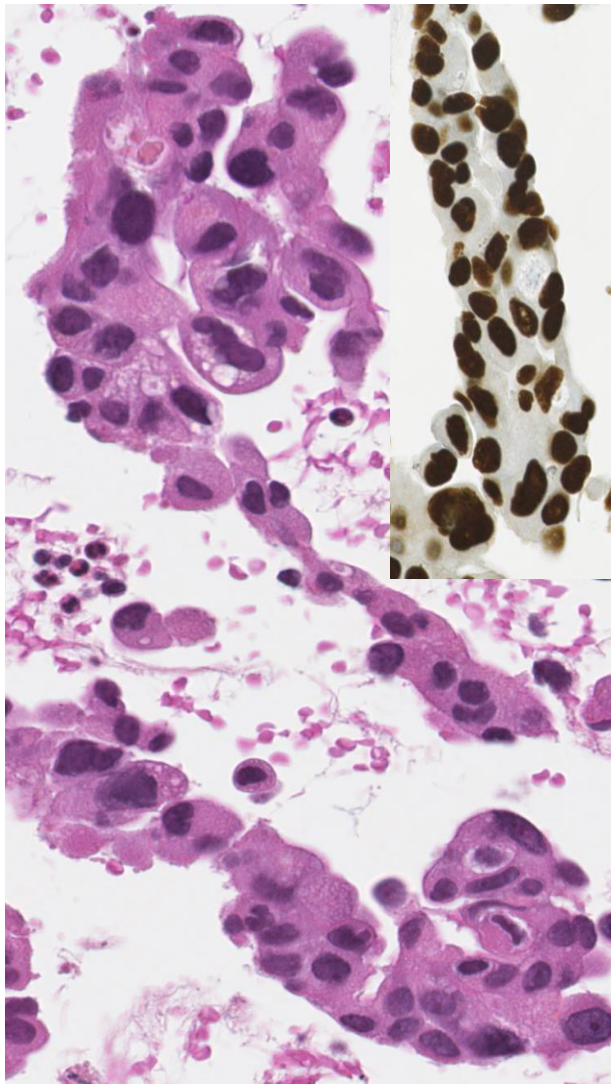

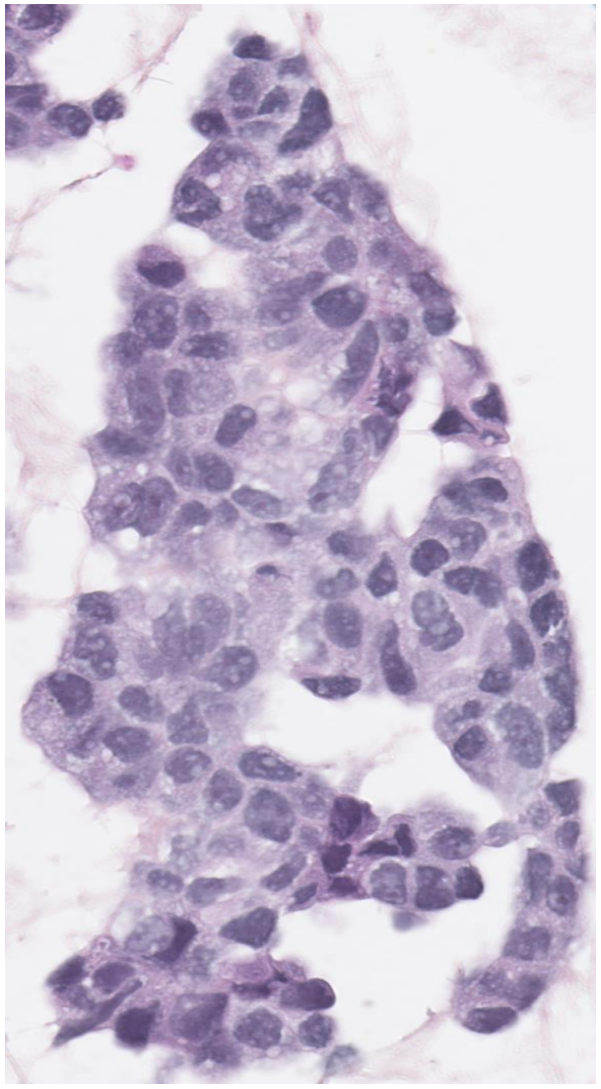

# Conclusion

- PEE : Examen de référence dans le diagnostic des tumeurs solides pancréatiques
    - Sensibilité > 85%
    - Cytobloc nécessaire en 2021
    - Echecs sont liés à la non représentativité et aux altérations cellulaires
    - Attention à une fixation inadéquate (cytolyt)
- Importance de disposer du CR d'EE … ou parler avec votre EE
    - Nature solide ou kystique de la tumeur, voie d'abord, suspicion diagnostic…
- Matériel de ponction est précieux
    - Tout faire pour essayer d'arriver à un diagnostic dès la première procédure ! afin de ne pas retarder la prise en charge